VOLUME 7 NUMBER 3 NOVEMBER 2023



CARDIOTHORACIC NEWS

An official publications of
Association of Thoracic and Cardio Vascular Surgeons of West Bengal

41, Sir Nilratan Sarkar Sarani, (Formerly - Creek Row) Kolkata - 700 014

Tel: : +91 9432455176

E-mail : actvswestbengal@gmail.com / cardiothoracicnews@gmail.com

Cardiothoracic News

An official organ of

Association of

Thoracic and Cardio Vascular Surgeons of West Bengal

Postal Address : 41, Sir Nilratan Sarkar Sarani, Kolkata - 700 014

Phone No. : +91 9432455176 (Mr. Amal Kr. Dey)

E-mail : actvswestbengal@gmail.com

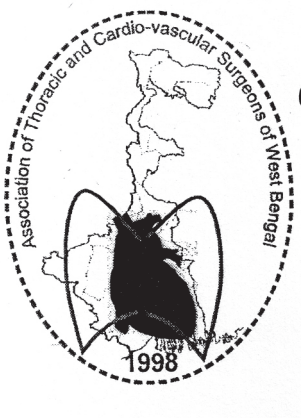

Association of Thoracic and Cardio-vascular Surgeons of West Bengal

41, Sir Nilratan Sarkar Sarani (Formerly Creek Row), Kolkata-700014.
Tel. : +919432455176, Email : actvswestbengal@gmail.com

Working Committee

President
Dr. Madhusudan Pal

Vice President
Dr. Ashis Mandal

Secretary
Dr. Gautam Sengupta

Treasurer :
Suranjan Haldar

Executive Members:
Dr. Santanu Datta
Dr. Subhendu Mahapatra
Dr. Md. Zahid Hossain
Dr. Swarnendu Datta
Dr. Arunansu Dhole

Past President:
Dr. Subhankar Bhattacharya

Cardio Thoracic News
Joint Editors:
Dr. Madhusudan Pal
Dr. Manoj Kr. Daga

Office Assistant:
Mr. Amal Dey (9432455176)

From the desk of President

"Education is a progressive discovery of our own ignorance..... Knowledge is the eye of desire and can become the pilot of the soul." -- Will Durant

Inter human contacts, thereby, interhuman exchanges of thoughts are the basis of society formations, success and human progress. Creation of history is one thing, history writing is different. History creators and history writers may be the same or may be different persons.

Work is part of Life. It should be honest, rational and purposeful. Yes, honest- i.e. with honest purpose for an ailing person. It may be proved wrong in subsequent investigations. It should be rational. Yes, rational- on the ground of all past experiences and knowledge. Purposeful- yes, which can not be random, haphazard, rudderless without a direction and purpose. We have not reached the end-point of the road of our journey of acquiring knowledge. Not to speak of the universe, even on the sciences related to our human body, we have to march a long way to fathom the hitherto mystery of composition and dynamics of our own body systems.

All ventures and adventures are needed by individuals and groups. Records of all these procedures and their results and even honest recording of mistakes are very important. Only analysis of these records will lead us to the next step with rationality. Our journey is, almost always, to unknown areas. Each operation is a journey and journey to areas, only partly known. Records of the mistakes of our predecessors will prevent us from repeating the same mistakes.

Records of our own experiences of our past operations will give us confidence. We are standing on the shoulders of our fore-fathers and on our own experiences. Any togetherness, any conference is an area of expression of our own thought process and also exchange of our thoughts. These exchanges give us new ideas and further stimulus for new works. Each conference has two purposes, stockpiling of experiences and flaming of new ideas.

Jai-ATCVSWB

Dr. Madhusudan Pal
President

Dr. Susmit Bhattacharya

Born on : 31st October, 1962 **Died on : 1st July, 2023**



Dr. Bhattacharya was an exemplary person both as a cardiac surgeon and as a human being. He spent his childhood in Orissa till he joined South Point School in 1972 in class VI. He completed (10+2) from West Bengal Board and stood 9th in WBJEE and joined his MBBS course in Calcutta Medical College in 1980. During his tenure in Calcutta Medical College, his stint as a house surgeon in the Cardiothoracic Surgery Department kindled his interest in cardiac surgery. Subsequently, he did his MS in General Surgery from Tata Memorial Hospital, Mumbai, and successfully qualified in DNB in General Surgery. His formal training in Cardio-thoracic surgery was in LMTG Hospital, Mumbai where he completed his MCH in Cardiovascular and Thoracic Surgery. Thereafter, he worked as an Assistant surgeon with Dr Sudhanshu Bhattacharya, where his grounding in cardiac surgery was strengthened. He came back to Kolkata in 1995 and joined Peerless Hospital (1995-99) as an Associate Surgeon. In subsequent years, he had worked in Ruby General Hospital (1999- 2003) and BM Birla Hospital (2003 - 2008). In 2008 he joined AMRI Hospital, Dhakuria as Chief Cardiac Surgeon and then continued in the same capacity in AMRI, Salt Lake from 2012 till his untimely demise from cancer on 1st July, 2023. During his illustrious career, Dr Susmit Bhattacharya was extremely popular with the hospital staffs and commanded great respect among friends, fraternity and patients alike, not only because of his extra ordinary and versatile skills as a cardiac surgeon but also because of his honest and endearing personality as a wonderful human being. We miss him so much in every step and our heart goes out to pray for eternal happiness for his departed noble soul.

Dr. Abani Kumar Biswas



Dr. Abani Biswas passed MBBS from NRS Medical college; MS & MCh from - IPGMER ; MNMS - from National Board of Exam, New Delhi; Fellowship from Philippines Heart Center of Asia, Manila. He was RMO cum Clinical Tutor in CTVS, IPGMER. He worked with Prof. S.M. Sengupta and Dr. Chayan K Roy in IPGMER from 1978 to 1984; after that he was transferred out to National Medical College as lecturer. He was a Life member of Cardiological Society of India, a person of sweet personality, always smiling, soft spoken. While attending the National Conference of IACTS in Ooty, he gave the idea of formation of the WB chapter. His idea got materialized after IACTS Conference in Calcutta under leadership of Prof. D. Saha and Prof. Sachinandan Banerjee. He was attached to CMRI for a long period and worked with Prof. Saibal Gupta. He left us for his heavenly abode on 29th July, 2023.

"HISTORY OF DEVELOPMENT OF BURDWAN TECHNIQUE OF OESOPHAGIAL DILATATION" by Prof. T. Addya and Dr Tarun Saha (Narrated by Dr Tarun Saha)

Dr. Prof. M. S. Pal

Sarveshwar Pramanick, a 17 years old male patient from Burdwan region, was frequenting to thoracic surgery OPD of Prof. Saibal Gupta in N.R.S medical College with stricture oesophagus by corrosive poisoning. His oesophagus was being dilated frequently. Stricture was in the region of the hilum of the lung. It was seen to have a diverticulum at stricture site on X - Ray barium swallow oesophagus. That made the situation difficult. Prof. Gupta and his team members in N.R.S medical College had to be very careful while dilating the stricture by Gum elastic bougie, gradual dilatation under general anaesthesia. After the transfer out of Prof. Gupta from N.R.S. Medical College, this patient lost contact with his doctors. By that time Prof. T. Addya and Dr. T. Saha. from N.R.S. Medical College have joined Burdwan Medical College in a newly formed unit of Cardiothoracic surgery. Now Sarbeswar started attending cardiothoracic surgery OPD in Burdwan medical College . Dr T Saha knew the case from before. Prof. Addya took the case very seriously with her usual motherly attitude. As the frequency of dilatation increased Prof. Addya thought to have some design of self and safe dilatation. Dr. Saha brought to notice of Prof. Addya a fact. In open gatherings, magicians or some Jajabars show the introduction of swords or metallic long rods into their own oesophagus from their mouths.

Can we not develop some such device? But the problem is diverticulum at the region of the hilum of the lung. How to be safe there near the hilum while introducing the dilator? Can we make self dilatation safe for antegrade dilatation or can we make a way for retrograde dilatation from the stomach side?

On pondering over the complex situation ideas came. Let the patient swallow a thin silk thread with liquid or semi solid food. Lower end of the thread went to the stomach gradually in periods of a few days. From the mouth the upper end of the thread was transferred to the nose by use of a ryles tube in the nasopharyngeal route . Under general anaesthesia gastrostomy was done for two purposes.

a. To take out the lower end of the thread from the stomach out of gastrocutaneous fistula (Gastrostomy)

b. To put one gastrostomy tube (wide malicot tube) in the gastrostomy for feeding

Now another two long and thick silks are attached to the lower end of the previously placed silk. From the nose the first silk is drawn up. The first thin silk is discarded. Now there are two long

thick silks from the nose to the gastrostomy site. Both the ends of the silks are secured by fixing them to skin by leukoplast. Now Narrow tip of a dilator can be tied with one silk in the gastrostomy site for retrograde dilatation. The dilator can be tied to the upper end of one silk for antegrade dilatation In that case the upper end of the silk needs to be transferred to the mouth from the nose to perform the manoeuvre. After the manoeuver the upper end of the silk is repositioned and fixed to the nose again. *Second silk is kept safe as the silk used in action may get torned.*

One Can increase the size of the dilator step by step. Subsequently. I saw Prof. Addya and Dr Sadhan Chandra Roy to develop a chain of gradually increasing plastic balls in place of gum elastic bougie.

During the manoeuvre, the feeding gastrostomy (FG) tube is temporarily taken out. After the procedure, the FG tube is repositioned for feeding of the patients for nutritional build up and the silk is also secured.

MANAGEMENT OF ESOPHAGEAL STRICTURE AND PROBLEMS OF FOOD CHANNEL CONFINED TO NECK BY TWO LAYERS OF LOCAL SKIN FLAP

Dr Prof M S Pal

During managing corrosive strictures of esophagus in NRS Medical College, RG Kar Medical College and Calcutta Medical College extending for nearly 34 years, I have come across three subsets of problems confined to neck regions.

i. Very high strictures in pharynx, where in one sitting anastomosing any part of the intestine to pharynx is a difficulty. Even if anatomical anastomosis is possible, functional success is near zero.

ii. After successful colon bypass, necrosis of the upper end of the colon near the pharyngeal anastomosis creates a hole anteriorly in the newly formed food channel.

iii. Stricture of esophagus confined only to the cervical Region where big surgery like Colon bypass can be avoided.

For the first subset: In one sitting colon bypass must be avoided. First step should be a high up pharyngostomy. Let the pharyngostomy mature in (4-6) weeks and allow to regain all pharyngeal reflexes for effective swallowing. Then the second step is to the colon bypass.

For Second subset: Fashion the gap as pharyngostomy and train the patient for pharyngostomy care. Let it to be mature for (4-6) weeks, let adequate skin, mucosa, granulation tissue grow in the area the closure of the pharyngostomy area in two layers of the skin (not rotation skin flap from forehead and upper part of pectoral region)

For subset three: wide long (long along the axis of the stricture cervical esophagus) pharyngostomy is done with wide liberal mobilization of Skin of neck, medial and lateral to pharyngostomy line (skin should be fill thickness with hypodermis with minimal use of diathermy) nd placing the skin flap into the tunnel of pharyngostomy, fixing them with interrupted suture (prolene or vicryl). Then to wait for (4-6) weeks for the maturation of the pharyngostomy, development of the pharyngeal and esophageal mucosa from islands of surviving mucosa, good union between skin end and mucosa, subsidence of the inflammations, growth of skin flaps and development of pharyngeal reflexes.

Prof Soumen Sengupta and Dr. Chayan Roy were closing small pharyngostomy (done in cases of esophageal foreign body removal) by two layers of local skin flaps. I extend this art of surgery for closure of larger gap in the food channel in the neck. After endotracheal intubation the neck extended and rotated to the opposite side (i.e. the right side) as pharyngostomy is always in the left neck. The widest possible gum elastic bougie is introduced from the oral side, passing

through pharyngostomy up to the distal esophagus.

Then, an Elliptical decision at adequate distance parallel to pharyngostomy on skin both on lateral and medial side one after another. Mobilizing the skin flap from distal side towards mucocutaneous junction without disturbance to newly developed mucocutaneous junctional continuity. Now both the flaps are inverted- that is epidermis inside and hypodermis outside. The flaps are sutured over gum elastic bougie with interrupted 2-0/3-0 vicryl. This is the inner layer of the new food channel. Then skins over the larynx box and lower neck near the midline are mobilized through the hypodermal plane. Similarly the skin from the posterolateral side of the neck is mobilized and these two layers sutured end to end with non absorbable monofilament suture This is the second layer of the food channel.

Total cases in the series were only eight in Calcutta Medical College. Positive aspect of this is to avoid forehead and pectoral flap which is not at all cosmetic particularly in younger age groups. Moreover it is simple to perform. But this technique is not without distant problems. Three of these cases developed re-stricture at the neck region after six to eight years of surgery, where I have to redo the surgery. The skin tube has a natural tendency to get fibrosis and create stenosis. This is to choose a lesser evil to avoid a bigger evil.

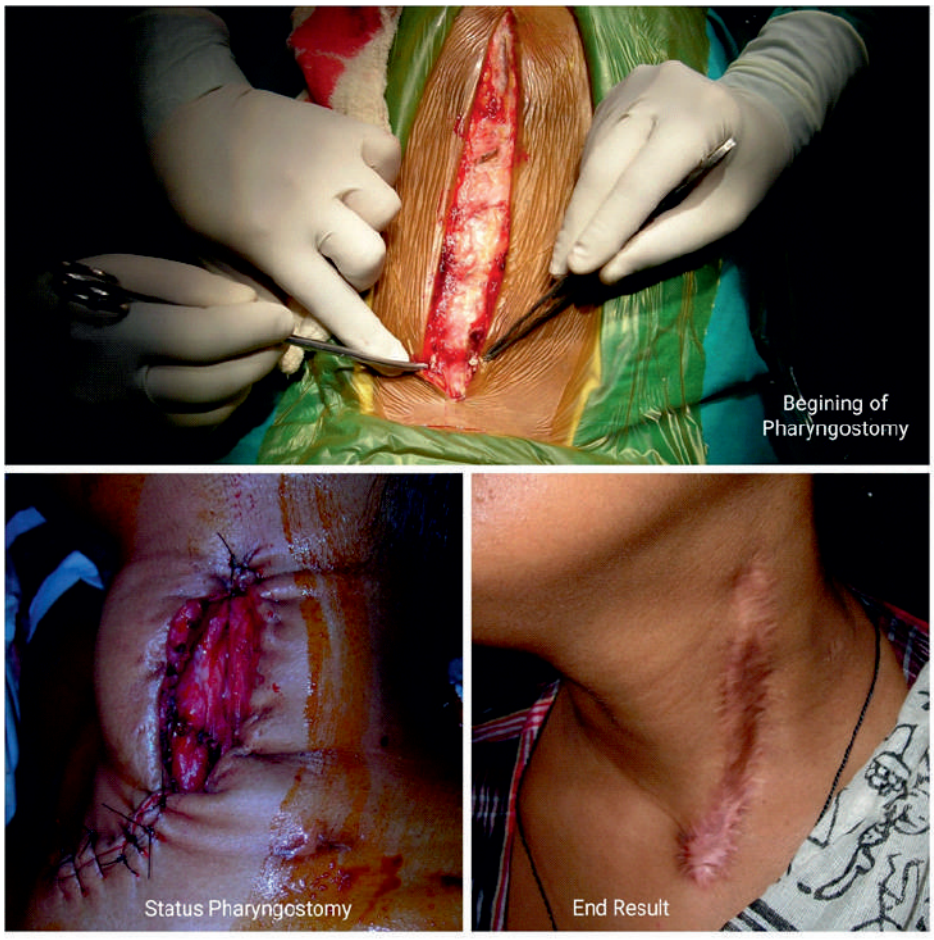

Arterial Switch Operation beyond Infancy : Our Experience

Susovan Halder, Debasis Das, Nilanjan Dutta, Manish Sharma,

Shivani Gajpal, Shubhadeep Das

Objective:

Children with transposition of Great Arteries with ventricular septal defect (TGA-VSD) often progress to irreversible pulmonary vascular obstructive disease if not operated on time. Irreversible pulmonary artery hypertension (PAH) renders the patients inoperable. Presence of left ventricular outflow tract obstruction (LVOTO) sometimes protects the pulmonary vascular bed and keeps the patient operable beyond infancy. Arterial switch operation remains a viable option in carefully selected group of patients. While arterial switch beyond 3 weeks of life is not so uncommon, this cohort of patients was rare as they presented beyond 1 year of age.

Methods:

- Observational study with data collected retrospectively from January 2020 to September 2022.
- We defined "Late" as any child presenting beyond 1 year of age.
- Apart from conventional echocardiography, 2 patients underwent oximetry and cardiac catheterization study.
- Echocardiography focused on LV parameters, mechanism of LVOTO and coronary anatomy.

Results:

- 9 patients were included in the group.
- 3 patients underwent ASO/VSD closure and LVOT resection.
- 3 patients underwent ASO and VSD closure.
- 1 patient had ASO and LVOT resection (previously had atrial septectomy).
- 1 patient underwent ASO only for TGA/IVS/Severe PAH.
- 1 patient underwent ASO, VSD closure and Aortic Valve Replacement for Severe AS.

Total number (n)	9
ASO/VSD closure/LVOT resection	3
ASO/VSD closure	3
ASO/LVOT resection	1
ASO	1
ASO/VSD closure/AVR	1
Previous procedure	Atrial septectomy in 1 patient
Mean CPB time	172 minites
Mean cross-clamp time	129 minutes
In hospital mortality	NIL
Mean postoperative hospital stay	7.4 days

Conclusion:

Primary Arterial Switch Operation is an option in late presenting patients of dTGA with VSD with or without LVOTO. Few patients with TGA, IVS also remain operable beyond the usual period probably due to pulmonary artery hypertension. But this subset of patients is very rare. However, primary ASO with or without associated procedures in late infancy or beyond always warrants careful pre-operative assessment and patient selection for optimal outcome. It would be interesting to see how pulmonary artery hypertension behaves in long term follow-up.

Spectrum and Outcome of use of Non-Invasive Ventilation in a Pediatric Cardiac Intensive Care Unit : A Single Center Experience

Shivangi Jain[3], *Shubhadeep Das[1], Minal Desai[2], Debasis Das[3], Nilanjan Dutta[3], Shivani Gajpal[4], Manish Sharma[4]*

1: Department of Pediatric Cardiac Intensive Care; 2: Department of Pediatrics; 3: Department of Congenital Cardiac Surgery; 4: Department of Cardiac Anesthesia Narayana Superspeciality Hospital, Howrah, India

Background:

The Pediatric Cardiac Intensive Care Unit (PCICU) frequently uses Non-Invasive Ventilation (NIV). There are several reasons for its application, including its prophylactic use right after the patient has been extubated. It is also used non-prophylactically when patients are experiencing acute respiratory failure (ARF) due to either cardiac or non-cardiac reasons but are still able to maintain their airway.

Objective:

1. To study the frequency of use of non-invasive ventilation and the clinical characteristics of children who required NIV for respiratory failure or prophylactic reasons after undergoing corrective or palliative cardiac surgery for congenital heart diseases
2. To determine the success and mortality rate of non-invasive ventilation identify factors predictive of increased use of NIV success in this population.

Methods:

- A retrospective observational study was conducted in a 14-bed PCICU, reviewing data of all children between the age of 1 day to 19 years who underwent corrective or palliative cardiac surgery [either with or without cardiopulmonary bypass (CPB)] between August 2019 to August 2022.
- All of these patients underwent either trans-esophageal echocardiography or epicardial echocardiography post-surgery after coming off from CPB, to define adequacy of repair and rule out major residual defects.
- We used Pressure Assist Control (PAC) Ventilation and Heated High Flow Nasal Cannula (HHFNC) Oxygen and as modes of delivery of NIV.
- When NIV was begun right after extubation, we either designated the patients into prophylactic groups, or when it was started after signs and symptoms of ARF, we designated them into nonprophylactic groups. Patients were labelled as responders if they received NIV and did not need tracheal reintubation throughout their time in the PCICU,

and nonresponders if they did not, necessitating tracheal reintubation.

- Typically we strongly considered the following subset of patients for putting on NIV: neonates and infants less than 5 kg, malnourished infants, children on prolonged invasive ventilation, low left ventricular ejection fraction during the time of extubation, those who showed signs of low cardiac output, cardiac surgery with a risk-adjusted classification for congenital heart surgery (RACHS-1) score of 3 and above, those with high vasoactive inotrope score (VIS) in 1st 24 hours of ICU stay, those with evidence of acute lung injury, those with a neuromuscular disorder, and those with suspected or confirmed diaphragm dysfunction.
- Demographic details, indication, duration and mode of NIV, interface (nasal cannula or full face mask), NIV failure, mortality, presence of pre and post operative infections, pre operative ventilator needs, diaphragmatic paralysis, PCICU LOS. Operative details including total intraoperative CPB time, aortic cross clamp time, RACHS-1 score were collected for each patient

Results:

- Among 1750 congenital cardiac surgeries, 523 patients (29.9%) received NIV. The median age of the population was 2.5 months.
- Of the NIV group, 53.9% were male and 46.1% were female. 205 children (39.2%) in the NIV group were neonates.
- PAC mode of ventilation was used in 33.4% patients, followed by HHFNC in 25.2% children and a combination of both in 41.3% patients.
- Factors such as higher RACHS-1 category, longer intraoperative CPB time, and aortic cross-clamp time were associated with increased NIV use.
- Pre-op ventilator needs, infections, genetic syndromes, diaphragmatic paralysis, high vasoactive inotrope score (VIS) in the first 24 hours, neonates, and weight less than 5 kg were independently associated with increased NIV need.
- The NIV group had a longer ICU stay compared to non-NIV patients.
- The success rate of NIV was 84%, with 440 successful cases and 83 failures.
- The mortality rate in the success and failure groups was not significantly different (5.27% vs. 6.0%).

Conclusion:

Our research highlights the common indications and factors associated with the use of NIV in PCICU. NIV has revolutionized patient management by reducing the need for invasive ventilation and its associated complications. However, our study reveals that NIV usage may lengthen ICU stays and does not reduce the mortality rates. NIV has a crucial role in cardiac critical care, but its use requires an unbiased approach. Our study's findings can guide future research, aiding a better understanding of NIV use in PCICU and its optimal application.

A COMPARATIVE STUDY TO ASSESS ROLE OF VIDEO-ASSISTED THORACOSCOPIC SURGERY IN PAEDIATRIC POPULATION IN A TERTIARY CARE HOSPITAL: ANALYSIS OF THIRTY PEDIATRIC CASES

Amitabha Chakrabarti[1], Manujesh Bandhyapadyay[1], Aryakamal Das[1], Apu Saha[1]

[1] *Department of Thoracic and Vascular Surgery, NH Rabindranath Tagore International Institute of Cardiac Sciences, Kolkata*

INTRODUCTION

The role of video-assisted thoracoscopic surgery is well established in adult population. With the development of proper instrumentation and devices, VATS can be employed in pediatric age group safely with favorable outcome. The aim of the study is to evaluate early postoperative outcome between children who underwent open thoracotomy and VATS for different surgical conditions.

MATERIALS AND METHODS

In this retrospective study, we included thirty (n=30) consecutive patients who underwent open or video-assisted thoracoscopic surgeries for any surgical indication in our hospital between June 2017 to August 2023. All relevant peri-operative data including diagnosis, procedure, postoperative ventilation hours, total drain output, blood transfusions, ITU stay and hospital stay were collected and analyzed using standard statistical tools.

RESULTS

In this study, thirty(n = 30) paediatric patientsunderwent thoracic surgeries of which twenty patients (n=20) were in open thoracotomy group and ten patients (n=10) were in VATS group. Mean age was 8.91 ± 4.93 years (95% CI [7.15; 10.67]), ranging between 8 months to 16 years. The mean bodyweight of the sample population was 30.41 ± 4.93 kg (95% CI [23.21; 37.61]), ranging between 6.45 to 97 kg.

Total 10 categories of surgery were documented, of which decortication was the most common surgery (n=12, 40%) performed both in open and VATS group.

Open thoracotomy was performed commonly in younger patient where mean age was 7.09 ± 4.59 years (95% CI [5.08;9.1]) and mean body weight was 23.23 ± 15.07 kg (95% CI [16.46;30.01]). Whereas VATS was opted for older children with mean age 12.56 ± 3.41 years (95% CI [10.45;14.67]) and mean body weight 44.04 ± 21.15 kg (95% CI [30.93; 57.15]).

Significant reduction in postoperative mean ventilation hours (9.9 ± 6.15 hours vs 14.2 ± 14.87 hours, $p < 0.001$), postoperative drain days (3.9 ± 1.2 days vs 4.6 ± 2.11 days, $p < 0.001$), total drain per kg body-weight (10.65 ± 6.72 ml vs 14.14 ± 16.58 ml, $p <0.001$), postoperative ITU stay (4.1± 1.97 days vs 4.3 ± 1.66 days, $p = 0.056$) and postoperative hospital stay (6.2 ± 1.55 days vs

6.8 ± 2.57 days, p = 0.015) were observed in VATS group as compared to open thoracotomy group.

In this study, blood transfusion was found to be more frequent in VATS group (1.89 ±1.45 unit) than open thoracotomy group (1.5 ± 1.54 unit), which was statistically significant (p = 0.003).

One patient (n=1, 3.3%) of the series, who underwent open decortication post Fontan completion, died due to sepsis with multi-organ dysfunction.

CONCLUSION

Video-assisted thoracoscopic surgery can be done safely in pediatric age group with comparable postoperative outcomeswith respect to open thoracotomy approach. Availability of appropriate instruments, skilled anesthetist and small chest cavity in children are the major limiting factors. Larger and randomized control study is required for the betterunderstanding of advantages and disadvantages of both approaches.

Surgical Management of Peripheral arterial disease in a tertiary Centre – A retrospective analysis

Amitabha Chakrabarty[1],Manujesh Bandyopadhyay[1], Apu Saha[1], Kajal P Barsainyan[1]

[1]Department of Thoracic and Vascular Surgery,
NH Rabindranath Tagore International Institute of Cardiac Sciences, Kolkata

Abstract

Objective:

To assess outcome of vascular repair for peripheral vascular disease in a tertiary hospital

Method:

We analyze 121 consecutive patients with limb ischemia from April 2015 to January 2022. We categorized the patients on the basis of presentation and etiology to assess primary amputation rate, limb salvage rate, medium term limb survival rate and 1 year mortality rate.

Results:

Of total 121 patients, 42.9% had emergency procedure. 57.1% had elective. 38.8% had acute presentation, 26.4% had acute on chronic presentation and 34.8% had chronic presentation. Atherosclerosis was the most common etiology (34.9%). 86.7% were taken for open surgical procedure and 13.3% were taken for hybrid surgical plus interventional procedure. 2.48% required redo procedure The overall primary limb salvage rate (90 days) was 93.4%, the primary amputation rate was 6.6%, The 6 months limb survival rate was 90.08% the 30 days mortality rate was 0.024%. The overall 1-year survival rate excluding loss of follow up (39) was 80.48%. The most common cause death was cardiovascular.

Conclusion

In conclusion, we assessed outcome of lower limb surgical vascular repair in a tertiary center with variety of etiological spectrum. This result was obtained in a tertiary care center with cardio-thoracic vascular surgery unit, not in an exclusive vascular surgery unit, where overall limb salvage rate and limb survival rate were acceptable which reduced morbidity of the patients following surgical repair.

In situ IMA ipsilateral to the AVF as a single inflow source in hemodialysis dependent patient

Bharath[1] MBBS, Swanand Khapli[1] MBBS, Azhar Sayyed[1] Dr N B, Lalit Kapoor[1] MCh

1-Department of Cardiac Surgery, NH Rabindranath Tagore International Institute of Cardiac Sciences, Kolkata, India

Coronary artery bypass grafting (CABG) demonstrates superior survival in patients with chronic kidney disease (CKD) on hemodialysis, who need revascularization for ischaemic heart disease(IHD). However, the conduit strategy for grafting remains unclear. The possibility of coronary steal associated with use of in situ Internal Mammary Artery (IMA) ipsilateral to an upper extremity arteriovenous fistula(AVF) is a major concern. Research on the use of in situ IMA ipsilateral to AVF as a single inflow source is rare, despite studies suggesting that this cohort's CABG patient with in situ IMA graft did not have any poor early or mid-term outcomes.

We present a case of total arterial revascularization done with an in situ IMA ipsilateral to the AVF as a single inflow source for CABG. During dialysis, a 50-year-old man with a history of hypertension, diabetes, and chronic kidney disease who was diagnosed with triple vessel coronary artery disease and severe left ventricular dysfunction presented with angina. Computed Tomography(CT) angiography of neck vessels ruled out any subclavian artery stenosis. He underwent an off-pump total arterial coronary artery bypass grafting, using an in situ IMA as the only inflow source ipsilateral to the AVF. After an uneventful postoperative recovery, patient is doing well on follow up with improved ventricular function and also undergoing hemodialysis without any complications.

Conclusion-

Composite Bilateral Internal mammary artery grafting based on an arterial inflow ipsilateral to the AVF in dialysis dependent patients is feasible and reasonable over venous grafting given the possible benefits. It can be offered in selected screened patients.

TO DETERMINE IMPLICATION OF INTRAOPERATIVE LEVELS OF $PaCO_2$, PO_2, NIRS AND DIFFERENCE BETWEEN JUGULAR VEINOUS OXYGEN AND RADIAL ARTERY OXYGEN LEVELS IN POST OPERATIVE NEUROLOGICAL OUTCOME IN PATIENTS UNDERWENT CARDIAC SURGERY- A RANDOMIZED CONTROL STUDY

Dr AKASH[1], Dr S.S MAHAPATRA[2]

1 MCH Resident, Department of Cardio Thoracic and Vascular Surgery, IPGMER & SSKM Hospital, Kolkata
2 Professor, Department of Cardio Thoracic and Vascular Surgery, IPGMER & SSKM Hospital, Kolkata

INTRODUCTION:

Neurological complication after cardiac surgery is an important predictor of post operative morbidity and mortality even in patients having no previous history of stroke[1,2,3] and in post operative period neurological insult can manifest in different ways like altered sensorium, cognitive dysfunction and focal neurological deficits[4,5,6,7,8].

Neuro-cognitive dysfunction may occur in 15-66% at the time of discharge and may persist even after 5 years post surgery in 40% of the patients [9,10] , incidence of stroke occur in 1.2-6% and risk of stroke exceeds in elderly [11,12,13,14] .

Several studies had been done to evaluate the risk factors for developing neurological complications in post cardiac surgery patients but many of the results incomplete and non decisive either due to low interventions or low number of variables, some studies shows association between long cardiopulmonary bypass and post operative stroke yet some studies also questioned this association [11,13,14]

Long duration of ventilation, history of stroke, pre and intra operative atrial fibrillation, hemodilution manifested by an HCT of <28% and long duration of aortic cross clamp are independent risk factors for neurological outcome and are also associated with high post operative mortality[15]

Hence the purpose of this study is to determine and evaluate the role of different patient, procedure and biochemical variables in the development of post operative neurological outcome following cardiac surgery.

OBJECTIVE:

Objective of this study is to effect of intra operative levels of Po2, PCo2, NIRS and oxygen saturation difference between jugular vein and radial artery in the post operative neurological outcome in patients underwent cardiac surgery on cardio pulmonary bypass support.

MATERIALS AND METHODS:

STUDY SITE: Study underwent in the department of cardio vascular and thoracic surgery, IPGMER & SSKM Hospital, KOLKATA.

STUDY POPULATION: Patients requiring cardiac surgery under cardio pulmonary bypass support.

STUDY DESIGN: This is a randomized control study.

STUDY DURATION: Study is taking for a period of one year between august 2023 to August 2024

SAMPLE SIZE: As per OT registry expected cases who underwent surgery requiring cardio pulmonary bypass support will be 100. Our sample size will be 80 with 95% CI (www.calculator.net/sample -size-calculator.html)

INCLUSION CRITERIA:

1. Patients undergoing cardiac surgery on cardio pulmonary bypass between age 15-65 years.

EXCLUSION CRITERIA: Patients who have

- Liver disease
- Renal disease
- Bleeding diasthesis
- Pre operative infection
- Pre operative anemia
- History of stroke
- History of brain trauma
- History of psychiatric disorders
- History of alcohol abuse
- History of neuro-psychotropic drugs intake

METHODOLOGY:

Following inclusion and exclusion criteria patients are divided into two groups

1. Patients underwent cardiac surgery on cardio pulmonary bypass surgery as cases.
2. Patients underwent cardiopulmonary and vascular surgeries under general anesthesia without cardio pulmonary bypass support as controls.

PREOPERATIVE STUDY VARIABLES:

1. Gender
2. BSA

3. Blood urea and creatinine levels
4. Blood glucose levels
5. Pre operative mini mental state examination(MMSE)

INTRAOPERATIVE STUDY VARIABLES:

1. Pre pump blood glucose levels
2. CPB time
3. Cross clamp time
4. Minimum temperature attained during CPB
5. Po2, PCo2 levels
6. Brain NIRS temperature introperative
7. Jugular vein oxygen saturation
8. Radial artery oxygen saturation
9. Difference between jugular venous and radial artery oxygen stauration
10. Total operative time
11. Estimated blood loss
12. Post pump glucose levels

POSTOPERATIVE STUDY VARIABLES:

PRE EXTUBATION PERIOD:

1. PCo2, PO2 levels on 6 hourly ABG monitoring
2. Jugular venous and radial artery oxygen saturation and their difference
3. Blood Ph levels on 6 hourly ABG monitoring
4. Estimated fluid intake and urine output 6 hourly
5. Blood glucose levels 6 hourly
6. Total time on ventilator support

POST EXTUBATION PERIOD:

1. MMSE [16]
2. Jugular venous and radial artery oxygen saturation 12 hourly and their difference
3. Ph, PCo2, PO2 on 12 hourly ABG monitoring
4. Fluid intake and urine output monitoring 12 hourly
5. Blood glucose monitoring 12 hourly

AFTER 3 MONTH FOLLOW UP:

1. MMSE

AFTER 6 MONTH FOLOW UP:

1. MMSE

STATISTICAL METHOD:

Study variables and results are express as mean and standard deviation student t-test and chi square test as indicated and P value < 0.05 consider as statistically significant.

REVIEW OF LITERATURE:

- Mc khan GM[1] et al in their update on stroke and encephalopathy after cardiac surgery states that Patients with preexistingcerebro vascular disease are at increased risk for these untoward neurological outcomes, which are associated with longer lengths of hospital stay, higher costs, and greater mortality. The mechanisms underlying these neurological events may include microemboli and hypoperfusion during surgery, and postoperative atrial fibrillation. Predictive models, based on information available before surgery, allow identification of these "high risk" patients.
- Kowalewski M[2] et al in their meatanalysis observe the comparative safety of two most commonly employed aortic clamping techniques for small thoracotomy MVS, TTC and endoaortic clamp by inclusion of 17 studies with 6643 patients it represents the largest database on the direct comparison of these two devices ever analyzed. The principle findings of the current analysis are as follows: 1. There was no difference between the occurrence of primary endpoint CVA at less than or equal to 30 days between the two strategies: 2. No differences were demonstrated for secondary outcomes all cause mortality and acute kidney injury: 3. EABO was associated with statistically significant nearly 5 fold increase in the relative risk of aortic dissection (with 4 fold increase of type A dissection) and numerically higher risk of leg ischemia as compared tp TTC: 4. There were no significant differences between 2 techniques with regard to duration of cross clamp and cardio pulmonary bypass with a trend toward shorter times in the TTC group.
- Newman MF[4] in their study over 261 patients underwent cardiac surgery on cardio pulmonary bypass and followed for 5 years shows strong relationship between neuro-cognitive functioning and quality of life and 5 year overall cognitive function scores were associated with lower general health and a less productive working status.
- Selnes OA[5] et al in a study over 127 patients underwent CABG on cardio pulmonary bypass support wit standardized neuro-psychological tests in pre-operative period found association of female sex, diabetes, lower PO2 levels on cardio pulmonary bypass

  Diseased cross clamp site, high BUN and creatinine level within 7 days in post-operative period, increased length of hospital stay are associated with high neuro-cognitive impairement.
- Raffe GM[6] et al in a meta-analysis of 17 retrospective case series shows that venoarterial(VA) extra-corporeal membrane oxygenation(ECMO) application in post-cardiotomy shock (PCS) and non-PCS including 1691 patients shows that there is no

statistical differences between peripheral and central VA-ECMO with regard to cerebro-vascular events, limb ischemia and sepsis rate.

- Bucerius J[10] et al in a risk factor analysis over 16,184 patiens shows that 10 variables which were independent predictors for stroke- history of cerebro-vascular disease, diabetes, peripheral vascular disease, hypertension, previous cardiac surgery, pre-operative infection, urgent operation, CPB time, need of intra-operative hemofilteration and high transfusion requirement. Beating heart CABG was associated with a lower incidence of stroke in this analysis.

REFERRENCES:

1. McKhann GM, Grega MA, Borowicz LM Jr, et al. Stroke and encephalopathy after cardiac surgery: an update. Stroke. 2006;37:562-71.
2. Kowalewski M, Malvindi PG, Suwalski P, et al. Clinical Safety and Effectiveness of Endoaortic as Compared to Transthoracic Clamp for Small Thoracotomy Mitral Valve Surgery: Meta-Analysis of Observational Studies. Ann Thorac Surg. doi:10.1016/j.athoracsur.2016.08.072.
3. Kowalewski M, Suwalski P, Pawliszak W, et al. Risk of stroke with "no-touch" - as compared to conventional off-pump coronary artery bypass grafting. An updated meta-analysis of observational studies. Int J Cardiol. 2016 Nov 1;222:769-71.
4. Newman MF, Grocott HP, Mathew JP, et al. Report of the substudy assessing the impact of neurocognitive function on quality of life 5 years after cardiac surgery. Stroke. 2001;32:2874-81.
5. Selnes OA, Goldsborough MA, Borowicz LM Jr, et al. Determinants of cognitive change after coronary artery bypass surgery: a multifactorial problem. Ann Thorac Surg. 1999;67:1669-76.
6. Raffa GM, Kowalewski M, Brodie D, et al. Meta-analysis of peripheral or central ECMO in Postcardiotomy and non-Postcardiotomy shock. Ann ThoracSurg 2018 Jun 27. doi: 10.1016/j.athoracsur.2018.05.063.
7. Gozdek M, Raffa GM, Suwalski P, Kolodziejczak M, Anisimowicz L, Kubica J, Navarese EP, Kowalewski M. SIRIO-TAVI group. Comparative performance of transcatheter aortic valve-in-valve implantation versus conventional surgical redo aortic valve replacement in patients with degenerated aortic valve bioprostheses: systematic review and meta-analysis. Eur J Cardiothorac Surg. 2018;53:495-504.
8. Raffa GM, Luca A, Badhwar V, et al. International participation in the Society of Thoracic Surgeons database improves outcomes: initial Italian experience. Ann Thorac Surg. 2016;101:2028-9.
9. Mahanna EP, Blumenthal JA, White WD, et al. Defining neuropsychological dysfunction after coronary artery bypass grafting. Ann Thorac Surg. 1996;61:1342-7.
10. Bucerius J, Gummert JF, Borger MA, et al. Stroke after cardiac surgery: a risk factor analysis of 16,184 consecutive adult patients. Ann Thorac Surg. 2003;75:472-8.
11. Baker RA, Hallsworth LJ, Knight JL. Stroke after coronary artery bypass grafting. Ann Thorac Surg. 2005;80:1746-50.
12. Wolman RL, Nussmeier NA, Aggarwal A, et al. Cerebral injury after cardiac surgery: identification of a group at extraordinary risk. Multicenter Study of Perioperative Ischemia Research Group (McSPI) and the Ischemia Research Education Foundation (IREF) Investigators. Stroke. 1999;30:514-22.

13. Floyd TF, Shah PN, Price CC, et al. Clinically silent cerebral ischemic events after cardiac surgery: their incidence, regional vascular occurrence, and procedural dependence. Ann Thorac Surg. 2006;81:2160-6.

14. Almassi GH, Sommers T, Moritz TE, et al. Stroke in cardiac surgical patients: determinants and outcome. Ann Thorac Surg. 1999;68:391-7.

15. Baranowska K, Juszczyk G, Dmitruk I, Knapp M, Tyci?ska A, Jakubów P, Adamczuk A, Stankiewicz A, Hirnle T. Risk factors of neurological complications in cardiac surgery. Kardiol Pol. 2012;70(8):811-8. PMID: 22933214.

16. Folstein M.F, Folstein S.E, McHugh P.R (1975). "Mini-mental state". A practical method fpr grading the cognitive state of patientsfor clinician. Journal of psychiatry research, 12(3). 189-98.

Lung Preservation in a Case of Complex Bronchial Injury

Prakash Sanki*, Nabarun Mallick, Jayita Chakraborty*****

** Head and Professor, Dept. of CTVS, IPGMER & SSKM*
***PDT, Dept. of CTVS, IPGMER & SSKM*
**** Associate professor, Dept. of CTVS, IPGMER& SSKM*

Introduction

Bronchial injury following blunt trauma chest is a rare occurrence in 0.2-8% cases. In only 30% cases a definitive diagnosis is made within 24 hours. We present a case where the bronchial injury was diagnosed and treated in a apparently symptom free patient following blunt trauma to chest

Case report

18 years male presented with history of road traffic accident- steering wheel impact on anterior chest wall 6 hours before attending the hospital . On examination- patient was moderately dyspneic at room air with stable vitals and no external chest wall wound. CXR done in emergency showed right pneumothorax with no mediastinal shift, no rib fracture. the patient was put on 10 It/min oxygen, ICD, 32F placed in right pleural space and the patient was stabilised after initial resuscitation. HRCT Thorax was advised

The patient was reviewed after 48 hours and was found to have grade 4C cerfolio air leak, surgical emphysema in thorax and neck, predominantly over right thorax. There was no dyspnoea at rest, vitals were stable and he was maintaining saturation above 95% in NRBM, but deteriorating to 80% in room air. Chest radiograph showed persistent collapse of right lung with right pneumothorax. Blood parameters did not show any featured of sepsis.

HRCT confirmed pneumomediastinum, Collapsed right lung more at upper and middle lobe, partial disruption of right bronchus near the origin of upper bronchus.

Following this, Plan for emergency surgical intervention after proper informed consent.

After taking the patient in operating room, Pre procedure ambuscopy showed injury over right bronchus

Intraoperative findings and procedure done:

- Entire right upper lobe consolidated with dusky discolouration
- One 7×4 cm deep laceration over the medial aspect of upper lobe
- Lower and middle lobe looked healthy and collapsed
- Mild adhesion with oedematous tissue at the posterior aspect of Nilima
- No free fluid

- o No vascular injury
- o Bronchial injury:
- o Wedge like avulsion of 2/3rd of anterior wall of right main bronchus at the junction of upper lobe bronchus
- o Complete avulsion of upper lobe bronchus from RMB with segment loss
- o Complete disruption of upper segmental bronchi at their confluence. Margin of Apical segmental bronchus was healthy.
- o Disruption of middle lobe bronchus.

Mobilization of right main bronchus done

- o Intraparenchymal dissection of each upper segmental bronchus was done to gain length of healthy bronchus
- o Dissection around middle lobe bronchus to gain length
- o Upper lobe anterior and posterior and apical segmental bronchus were sutured together in continuous fashion to make a common confluence and the confluence was reimplanted on the RMB
- o Anterior wall of RMB was suture repaired
- o Middle lobe bronchus was directly reimplanted over RMB
- o Total repair was reinforced with intercostal muscle flap.
- o Very minimal air leak on bag ventilation
- o Adequate expansion of lower and middle lobe seen
- o Minimal expansion of consolidated upper lobe
- o On table ambuscope showed no dehiscence along the suture line.

Post-operative period:

The patient was extubated after 3 hours in ICU. Initially there was air leak on forceful expiration, which stopped spontaneously on 4th pod. Serial monitoring with chest radiograph showed complete expansion of middle and lower lobe with white out upper lobe which gradually improved partially subsequently with partial reappearance of air bronchogram. We had performed check bronchoscopy on 7th pod which showed healthy bronchial repair margin with minimal slough tissue. Middle and lower lobe bronchus healthy. Upper apical segmental bronchus was healthy with no stenosis. Partial stenosis in anterior and posterior segmental bronchus was noted. Bronchoscopic lavage and suction was done.

Following bronchoscopy, in subsequent 7 days upper lobe air entry improved with more appearance of air bronchogram with minimal residual wedge like white out consolidation at the peripheral part of middle part of upper lobe. There was No c/o cough, expectoration, fever, no oxygen demand and the patient was discharged on 14th pod.

Discussion

2.5-3.2% of patients who die as a result of trauma may have associated tracheo bronchial injury. Tracheobronchial injury (TBI) in blunt chest trauma occurs in 0.2% to 8% cases. In only 30% of cases is a definitive diagnosis made within 24 hours of injury. 80% lesions are within 2.5 cm of carina. Mainstem bronchus and right main bronchus is more affected than left main bronchus. Usual Presentations are dyspnoea, surgical emphysema, tension pneumothorax, persistent pneumothorax, collapsed lung. Rarely they can be asymptomatic

Massive air leak and inability to re expand of lung after tube thracostomy is highly indicative of tracheobronchial injury.

Basic investigation includes- chest X-ray, MDCT of thorax, bronchoscopy

Basic mechanism of tracheobronchial injury are- 1) rapid increase in airway pressure against closed glottis by sudden chest compression. 2) extensiveanteroposterior chest compression forcing lungs laterally and causing rupture of central airway near carina. 3) Rapid deceleration with shearing force applied to the fixed part of trachea and causing rupture of mobile part of trachea.

Principle of management:

- secure airway- inflation of cuff beyond injurySingle lung ventilationBronchoscopy guided intubationlow tidal with minimal positive pressure ventilation cardiopulmonary bypass support in extreme cases
- Conservative management- limited role in <2 cm longitudinal lesion or <1/3rd circumferential lesion with membranous portion only involvement without any injury. Minimal or no requirement of ventilators support
- Surgical management-
- primary repair, sleeve resection, bronchoplasty
- Can Consider lobectomy if disruption of one lobar bronchus not amenable to repair
- Primary repair by interrupted, running or telescopic technique using absorbable suture.
- Principle of repair- 1) trachea to be mobilisedantero posteriorly

2) not more than one half of the trachea(8-10 rings). should be resected

3) Release manoeuvre can be considered to minimise tension at anastomosis line

- Post repair mild stenosis, lung atelactesis, granulation tissue take time up to 9 months
- Long term follow up with serial chest ray, bronchoscopy and CT scan as and when required

Conclusion

Lung preservation can be considered in well selected cases even with complex tracheobronchial injury. Long term follow up, strict surveillance, adherence to treatment plan and good compliance from patient end are all that are required for a successful management such complex injury.

References

1) vanRoozendaal LM, van Gool MH, Sprooten RTM, Maesen BAE, Poeze M, Hulsewé KWE, Vissers YLJ, de Loos ER. Surgical treatment of bronchial rupture in blunt chest trauma: a review of literature. J Thorac Dis. 2018 Sep;10(9):5576-5583. doi: 10.21037/jtd.2018.08.22. PMID: 30416808; PMCID: PMC6196165

2) Glazer ES, Meyerson SL. Delayed presentation and treatment of tracheobronchial injuries due to blunt trauma. J SurgEduc 2008; 65: 302-308.

3) Sharma P, Sharma A, Mehdi KM, et al. Outcome analysis of tracheobronchial injuries at a large service hospital. Int J Sci Stud 2018; 6: 47-52.

4) Jamal-Eddine, H., Ayed, A.K., Peric, M. et al. Complex bronchial ruptures successfully treated with primary reconstruction and limited lung resection. Gen ThoracCardiovascSurg 57, 261-263 (2009).

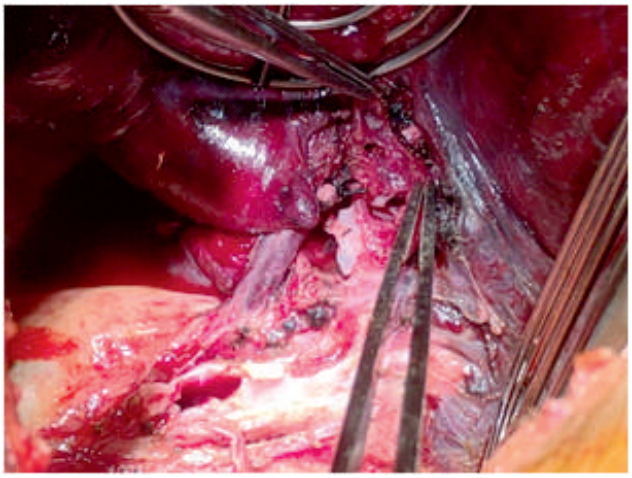

Bronchial injury

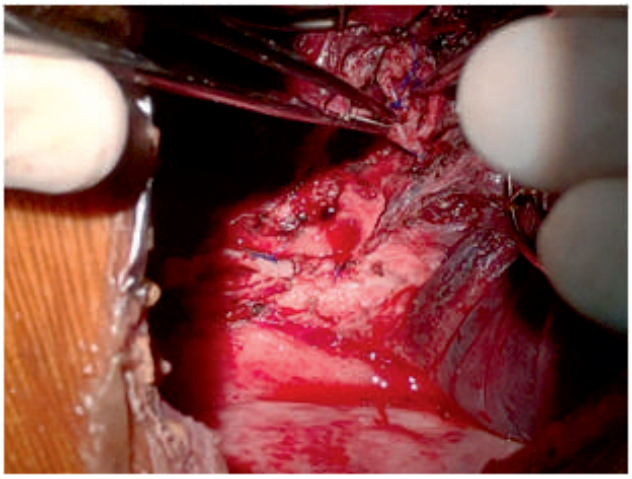

creation of confluence of apical and anterior upper segmental bronchus

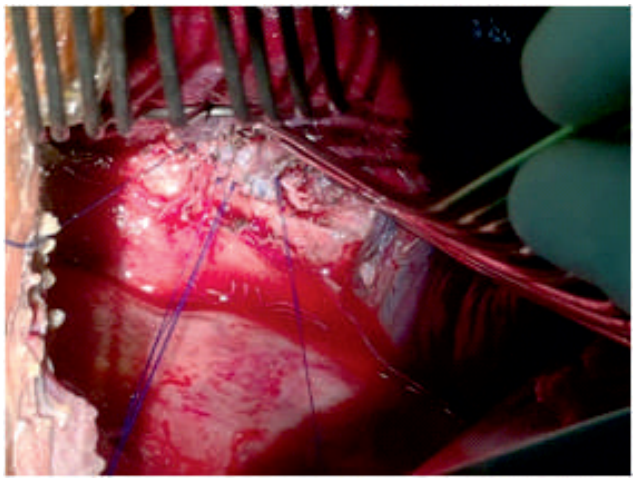

Post repair

A NOVEL, COMBINED SINGLE-STAGE APPROACH FOR REPAIR OF DIFFICULT EXTENSIVE AORTIC PATHOLOGIES- EXPERIENCE IN A TERTIARY CARE CENTRE OF EASTERN INDIA

Unmesh Chakraborty

ABSTRACT

Background: Of late, aortic surgery with various stent grafts and other interventional procedures are being performed widely in patients with thoracic aortic disease. Treating complex conditions affecting the arch and proximal descending thoracic aorta, such as arteriosclerotic aneurysms spanning the entire thoracic aorta, type B aortic dissections accompanied by dilation in the proximal descending or ascending aorta, or aneurysms with intricate anatomical features, remains a formidable clinical challenge. This challenge is particularly pronounced when these conditions coexist with severe sclerosis.

We report our surgical experience using a novel, combined approach for such repairs using a simultaneous anterolateral thoracotomy and midline sternotomy and its benefits.

Methods: Patient is kept in supine position with left shoulder elevated by 30-45 degrees, as shown in the figure. Surgical approach to the chest is made via a midline sternotomy and a 5 to 10 cm long left anterolateral thoracotomy via the fourth intercostal space, which may be lower depending on the extent of the pathology. The sternum and ribs are retracted separately. The entire thoracic aorta, is well visualised and excellent access to the arch vessels and even distal limit of the disease is achieved. Establishment of cardiopulmonary bypass,is done by the right axillary artery cannulation via a sidegraft and if needed, left femoral artery is cannulated as well to ensure good distal organ perfusion. If Circle of Willis is not patent, selective carotid as well as left subclavian cannulation is also done to take care of neuroprotection. The right atrial appendage was cannulated for venous drainage. Left heart bypass is performed through the right upper pulmonary vein. Cooling is done till 28 C and then the heart is arrested using del Nido cardioplegia. Low flow circulation is maintained at about 20 degrees celsius. First, open distal anastomosis is performed to reduce spinal cord ischemia and then the proximal repair is completed. The proximal suture line is usually moved from the zone 3 to zone 2,as it gives us a better and safer suture line due to more fibrous nature of the area, and prevents any leak. Subclavian reimplantation is done easily onto the graft. After completion of the procedure, rewarming is done and both proximal and distal extent of the neo-aorta is visualised satisfactorily.

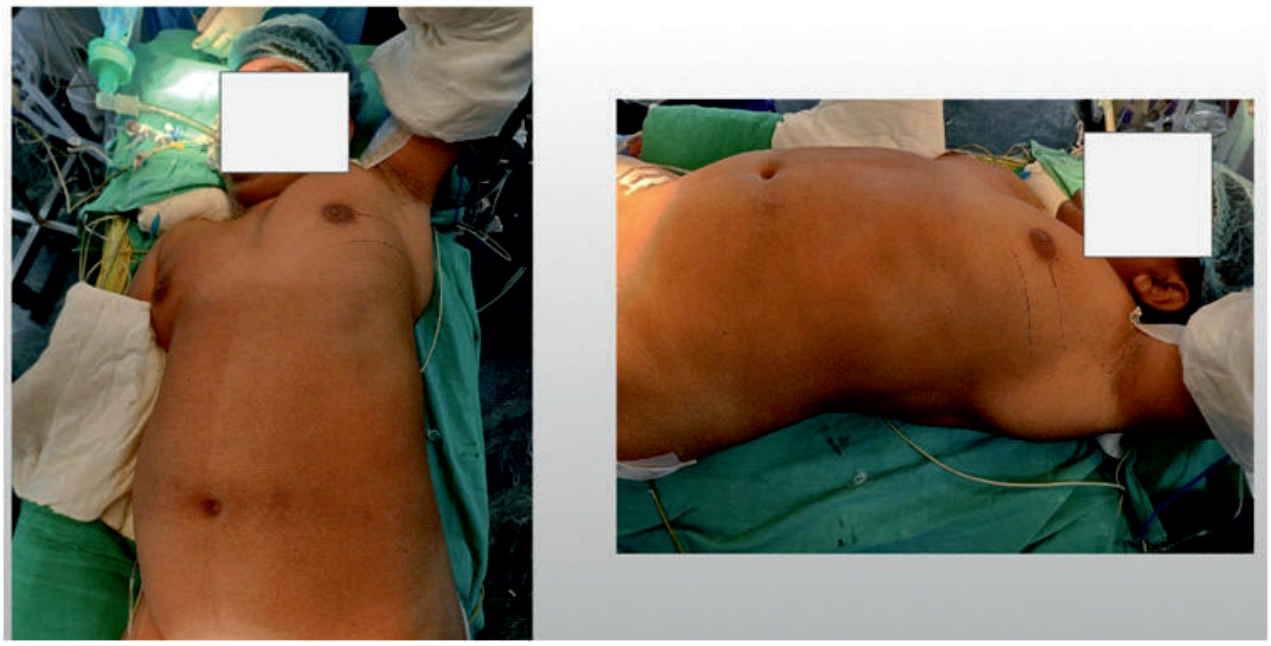

Figure 1- Real life scenario (patient identity not disclosed) of patient positioning with slightly inclined and elevated left shoulder and hip

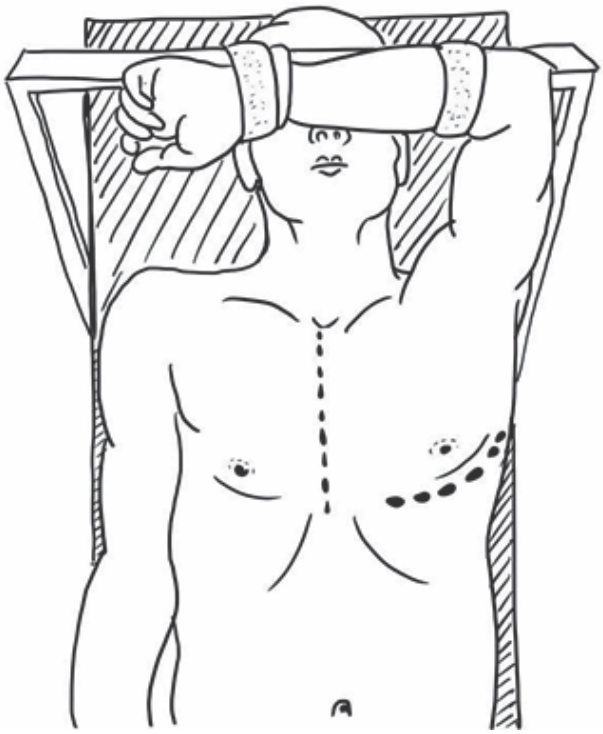

Figure 2- Line diagram of the positioning of patient

PATIENT CHARACTERISTICS (shown via reconstructed, 3D computed tomography images of a few patients in our series)

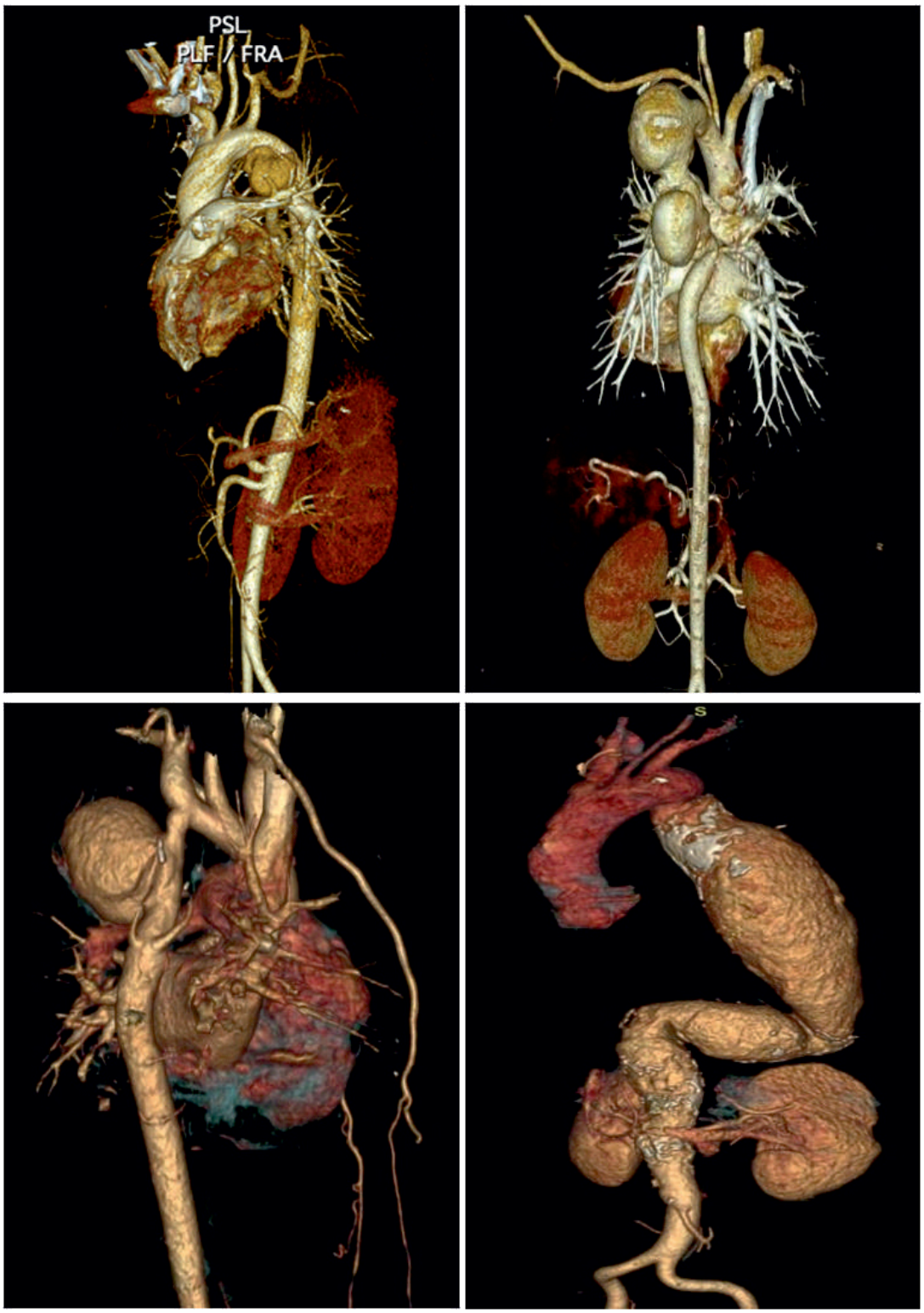

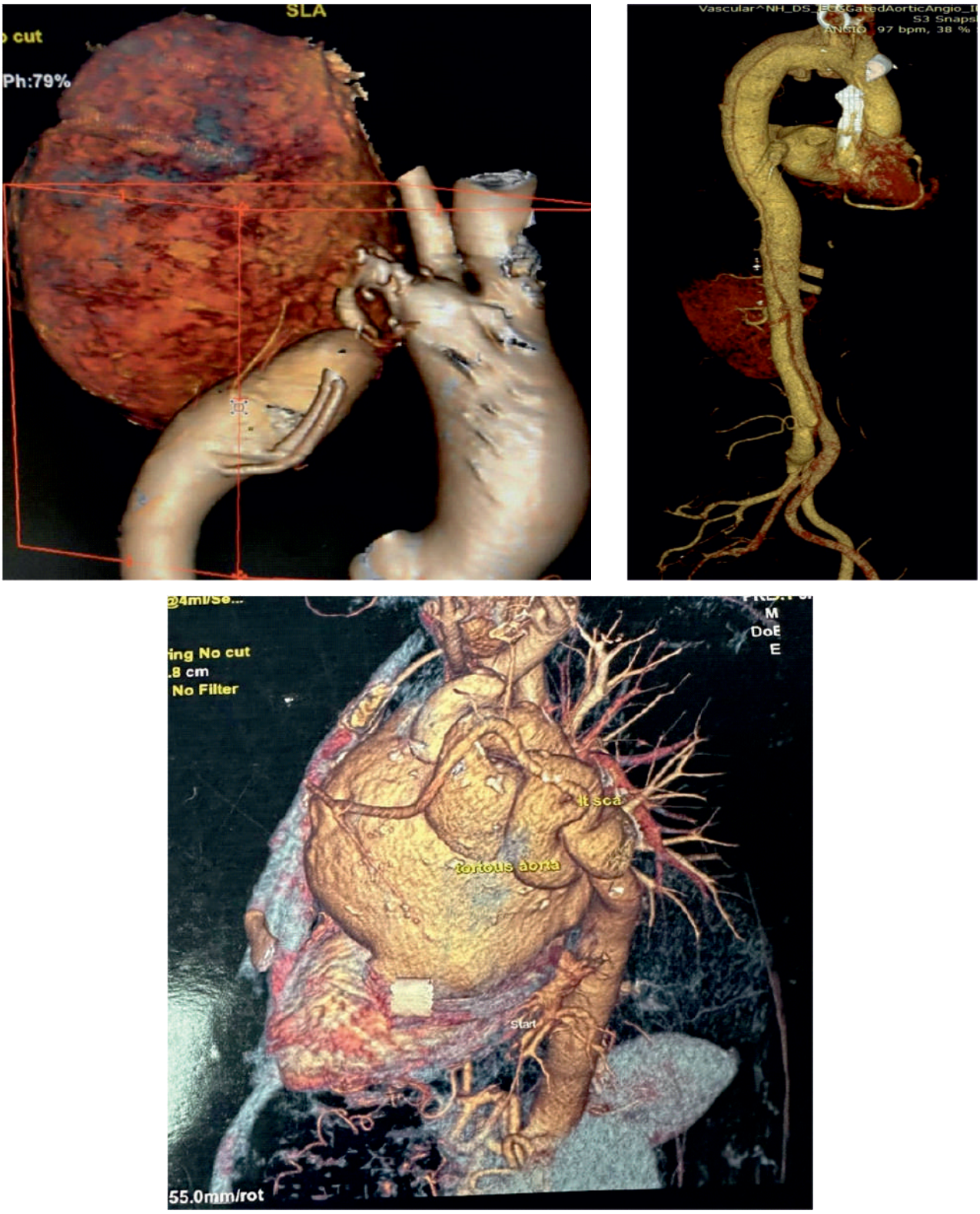

Some preoperative CT images of complex aortic pathologies in our series

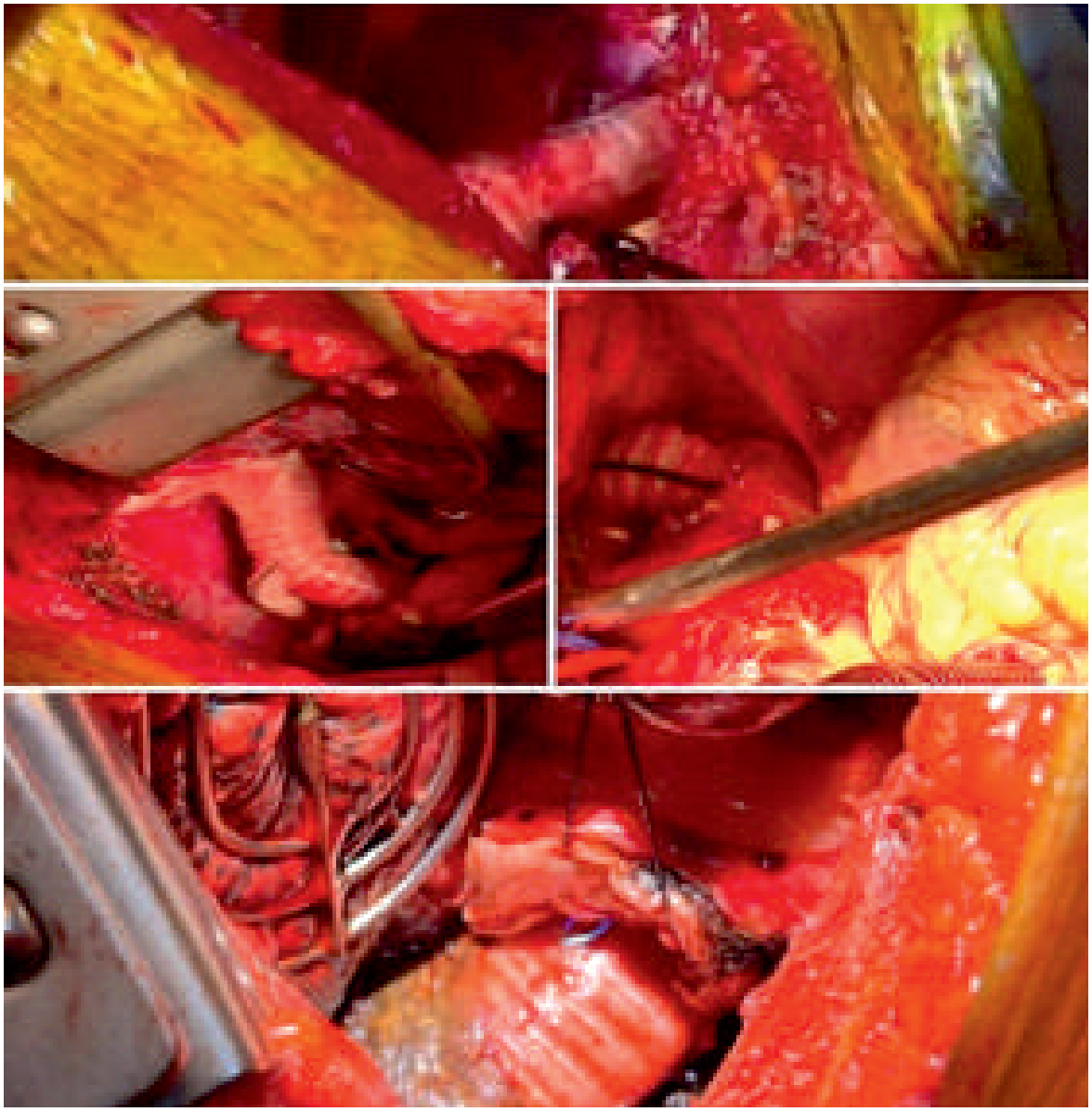

Excellent visualisation of proximal and distal limits of anastomosis, via simultaneous incisions.

Results: There were a total of 17 patients, included from January 2021 to September 2023, who underwent surgery for their complex aortic pathologies. There were no incidence of stroke, renal failure, spinal cord ischemia. There was no mortality in our series. One patient needed a reintervention via TEVAR. One patient developed Chylothorax which needed surgical drainage. 3 patients had recurrent laryngeal nerve paresis, but the hoarseness in their voices resolved over time. One patient had a transient posterior cerebral artery infarct which responded to conservative management. Mean cardiopulmonary bypass time was 247 minutes with a mean of 183 minutes aortic cross clamp time. Adequate neurological protection was usually achieved by low flow circulation. All patients are doing well, without any symptoms,on follow up.

Discussion: Extended aortic pathologies, necessitating repair involving the ascending aorta, aortic arch, and descending aorta continue to remain a challenge. A Two-stage approach to treat combined lesions is performed frequently. The classical elephant trunk technique or even the frozen elephant trunk technique has greatly facilitated surgery on this kind of diseases as well. Thoracic endovascular aortic repair (TEVAR) is also becoming increasingly popular for these. However, a well-known disadvantage of this two-staged approach is that the cumulative mortality, which includes in-hospital mortality for the 2 procedures and aortic rupture in the interval between them, is high. To reduce the cumulative risk of the staged approach, some surgeons prefer single-stage repair of extensive aortic aneurysms with a clamshell incision, and even extended left lateral thoracotomy. TEVAR carries its own downsides of not being able to negotiate difficult anatomies, chance of endoleak, high reintervention rate, endograft migration, and overall loss of any benefit in mortality and morbidity beyond 2 years. Hybrid arch repair also continues to remain controversial because of its unknown long-term durability. These modalities were absolutely impossible to be performed in the complex cases highlighted above.

While the prospect of utilizing two long incisions may initially raise concerns about increased morbidity, the substantial advantages of this approach in terms of enhanced visualization and access, ensuring proper distal body perfusion, and facilitating precise surgical techniques far outweigh the associated complications. In our experience, the drawbacks, including postoperative pain, duration of hospital stay, overall mortality, incidence of stroke, and the need for re-interventions, are minimal and fall within acceptable limits.

These benefits collectively contribute to the establishment of a stable and secure framework for myocardial and cerebral protection, ensuring effective management of aortic repairs. Especially in resource-constrained settings where cost is a significant limiting factor, the single-stage combined surgical approach for such cases emerges as the preferred choice.

Conclusion: Single-stage repair is still needed, especially for patients with anatomical difficulty. With this novel combined surgical approach, via left anterolateral thoracotomy and median sternotomy we get the advantage to not only achieve adequate arterial and venous cannulation, ventricular venting, and cardioplegia but also provide a surgical field of the whole thoracic aorta. In addition, antegrade selective cerebral perfusion if needed, can also be easily performed. Our series with a relatively small pool of patients had heterogenous disease identity. Long term data of a large cohort of such patients is needed to arrive at a definite conclusion.

Tricuspidization of diseased bicuspid aortic valve with autologous pericardium based on the Ozaki technique- A case report

Prakash Sanki*, Rituparna Dasgupta**

**Professor & Head of Department, Dept. of CTVS, IPGMER & SSKM Hospital, Kolkata*
***Post doctoral trainee, Dept. of CTVS, IPGMER & SSKM Hospital, Kolkata*

Introduction

Aortic valve repair/ sparing procedures are now the treatment of choice for patients with aortic regurgitation and root aneurysms, specially in younger patients, and aortic valve replacement with mechanical / bioprosthetic valves have been recommended for patients with aortic stenosis, since no ideal aortic valve substitute has been discovered yet [(1)]. However, prosthetic valve implantation has limitations like structural degeneration, need for lifelong anticoagulation, infection, and stuck leaflets.Bioprosthetic valves have a propensity for degeneration after 10-15 years in adults, and faster in younger patients due to immunologic reactions [(2-4)]. Aortic valve repair and valve sparing techniques overcome these limitations. Although various tissues have been used for such repair, the treated autologous pericardium has shown the best results in terms of durability [(5-8)]. In cases of severe calcification and degeneration, such a repair may not be feasible, and therefore the concept of AVNeo or complete neocuspidisation of the aortic valve with autologous tissue was described by Duran and colleagues, where freedom from reoperation was 47% at 16 years follow up [(9,10)]. Ozaki and colleagues, and Takahashi and colleagues reported excellent mid term results with Aortic valve neocuspidization using treated autologous pericardial patch [(11-14)]. Complete native valve removal thus facilitates use of this technique in almost all aortic valve diseases like Aortic stenosis, regurgitation, infective endocarditis, Prosthetic valve endocarditis, degenerative diseases and even root aneurysms in which root replacement with AVNeo is gaining popularity. The greatest advantage is that hemodynamics of the neocusps is almost similar to that of the native valve and is often better [(15-17)].

This case report discusses about a 36 year old male diagnosed with severe symptomatic high gradient Aortic stenosis with moderate Aortic regurgitation in bicuspid aortic valve who was treated with aortic valve neocuspidization using treated autologous pericardial patch with a satisfactory outcome in short term follow up.

Case presentation

A 36 year old male with exertional dyspnoea (NYHA III) since past 8 months was investigated and 2DTransthoracicEchocardiography revealed LVEF 63.8%, thickened and heavily calcified bicuspid aortic valves, AS gradient-47.7 mm Hg(mean), 72.74 mm Hg (max),AVA-0.56 cm2, LVOT VTI-94.2cm , AV VTI-94 cm, AV Vmax- 4.5 m/s, LVOT diameter -18.8 mm, ARPHT-340 ms, ARVC- 0.54 cm, concentric LVH, asymmetrical septal hypertrophy, no PAH, normal mitral leaflets, and trivial TR. As per valve hemodynamics and anatomy in 2D ECHO, he was

diagnosed to have symptomatic severehighgradient Aortic stenosis (Stage D1) withmoderate Aortic regurgitation (Stage B) with left ventricular hypertrophy in bicuspid aortic valve.He had a normal coronary angiogram and other routine investigations. He was planned for elective surgery and proper informed consent and patient preparation was done. An on table preoperative Trans- Esophageal Echocardiography corroborated with the above findings.

The first step of the surgery, following a median sternotomy and pericardiotomy was preparation of the pericardium.A 7cm ×7 cm of pericardium was excised and wascleared of fat and redundant tissue. It was immersed in 0.6% buffered glutaraldehyde solution for 10 minutes and then rinsed three times with saline solution for a total of 20 minutes [Fig.1]. CPB was established via aortic and dual stage right atrial cannula. Cold blood cardioplegic arrest was done at 30 degrees centigrade. Aortic valve wasexposed via partial aortotomyat 1.5 cm above the right coronary ostiaand was seen to be bicuspid, having severely calcified leaflets and commissural fusion.

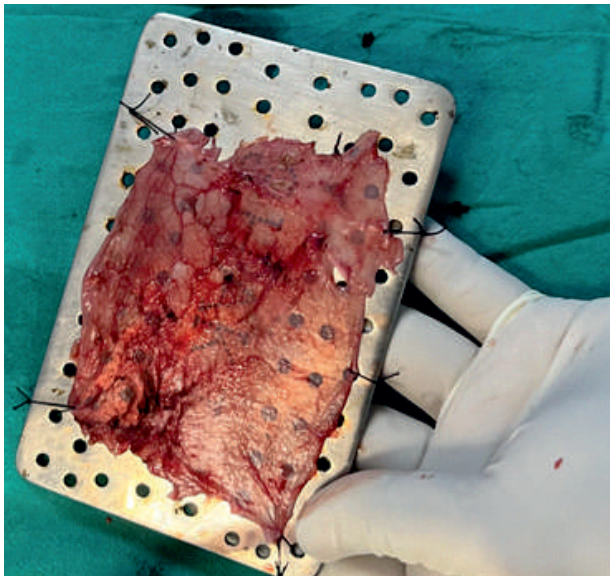

Fig.1: Preparation of pericardium

The diseased cusps were excised, extensive annular decalcificationand left ventricular wash with normal saline given. The intercommisuraldistance was used as a reference for adequate sizing of the cuspsand was measured with callipersusing appropriate tension and found to be 19 mm and 21 mm. The proposed new commisure wasmarked at the existing rapheaccording to recommendations by Ozaki and colleagues. A number 19 SJM aortic valve sizer was found to be adequate for the patient as per BSA and valve sizer. The autologous treated pericardium was then tailored according to the customised Ozaki based template to create 3 aortic leaflets- 2 leaflets of No. 19 size and 1 leaflet of No.21 size [Fig.2]. The neocuspswere sutured to the annulus using single running 5-0 prolenestarting at the nadir of the annulus and moving bidirectionally towards the commissures.Lateral margin of each cusp was sewn with a little plication of the inner pericardium facing the aortic wall which helps in resistance of stress and optimises coaptation.

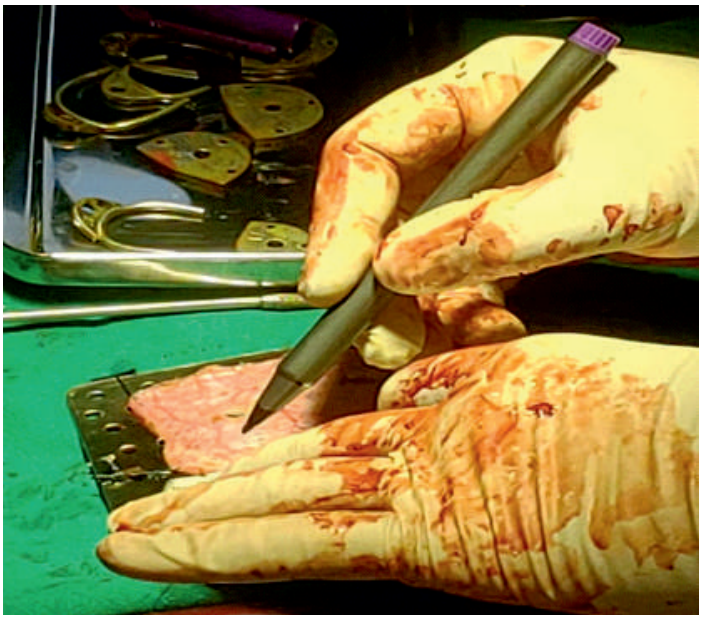

Fig.2: Neoleaflet sizing based on inter-commisural distance

Additional commissuroplasty using 5-0 prolene through the neocusps, above the last bite of the running suture was given to secure thecoaptation point and fit the plicated cusp to the aortic wall [Fig.3].

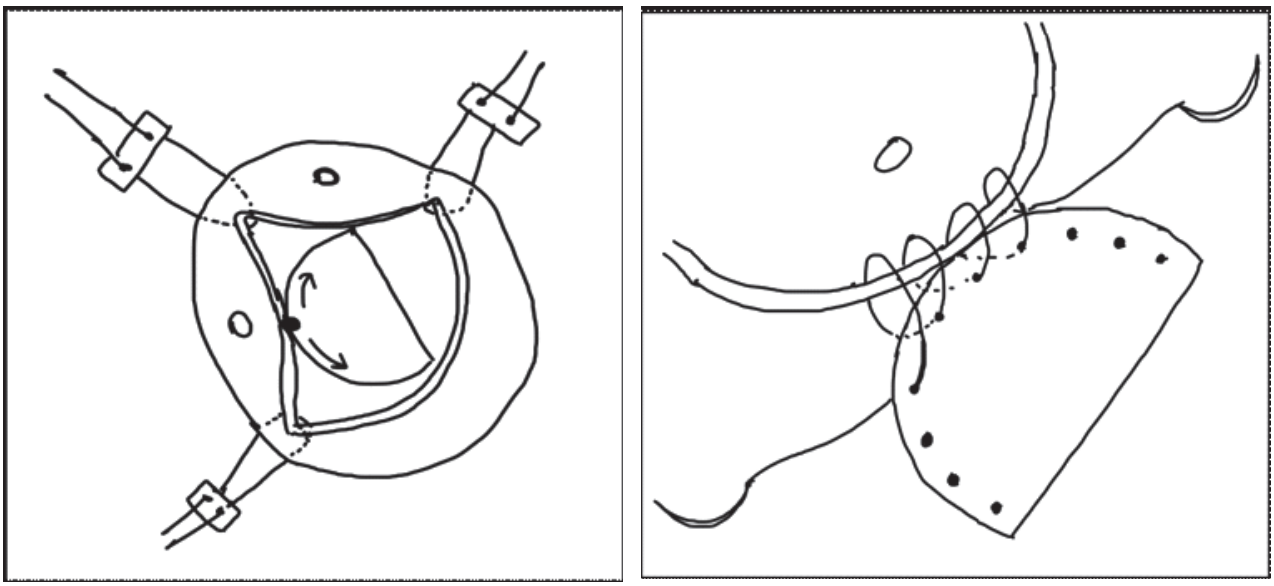

Fig.3: Suturing of the neocusps to the annulus

Both the running annular suture and commissural stitch were tied on the outer side of the aorta, with the interposition of a felted pledget. After the resuspension of the three neocusps, a visual check, negative pressure made by the left ventricular vent and valvecoaptation testing with

normal saline flush was done to evaluate the degree of the coaptation and was found to be satisfactory [Fig.4]. Aortotomy closure was done and weaning from CPB was uneventful. CPB time was 127 minutes and myocardial ischemic time was 100 minutes. Immediate post procedure TEE showed beautifully coaptedaortic valve cusps in both mid oesophageal short and long axis view [Fig.5].

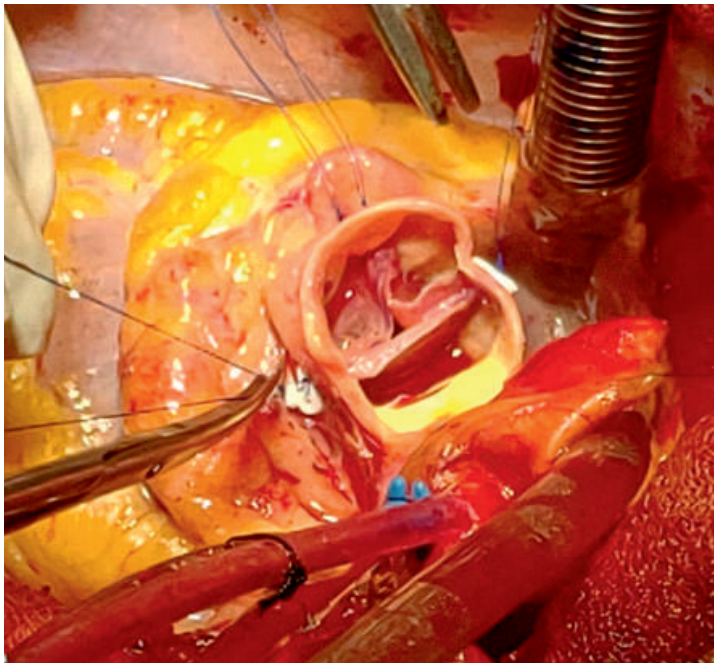

Fig.4:

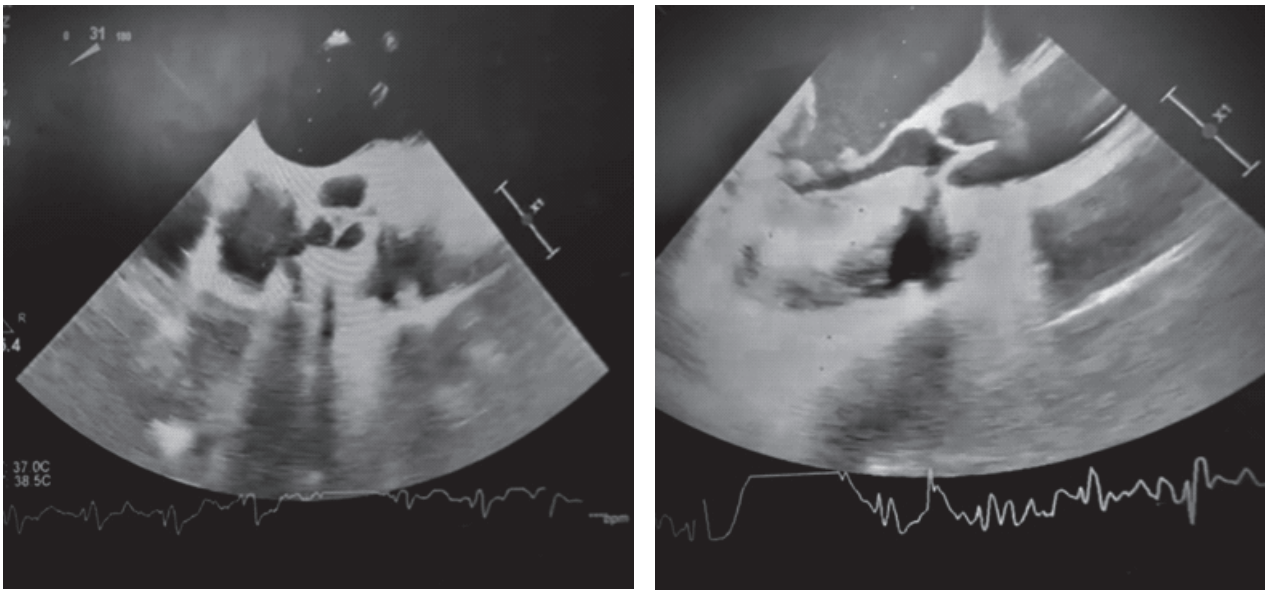

Fig.5: Immediate post procedure TTE showing valve coaptation and increased coaptation height

Post operative recovery was uneventful. Patient was discharged at 5th post operative day with low dose aspirin, and with repeat echocardiography showing no residual AR and proper coaptation of the aortic neo-cusps. Aortic valve velocity and pressure gradients were within normal limits.Patient was doing well at 6 months follow up and a TTE showed good cusp coaptation, AV Vmax 103 cm/s, EOA 2.19 cm2, and LVOT VTI -12.8 cm.

Discussion

The reconstruction of the aortic cusps based on the technique described by Ozaki et al is highly reproducible and has excellent mid- and long-term results. In 2011, initial experience of 88 patients were reported with a mean age of 70.6 years with 65 patients having aortic stenosis. At 3 years of follow-up, freedom from reoperation was 100%. In 2012, an experience with 9 patients having unicuspid aortic valves were reported with a mean follow-up of 1.5 years [11,18]. They emphasized the importance of tricuspidization and that there were no reoperations during the follow-up period. In 2014, they described their experience in 102 patients having bicuspid aortic valves [13]. In 2018, an overall experience with 850 patientswere documented. Aortic stenosis was the predominant diagnosis in 534 patients. Longest follow-up was 118 months. There were 15 reoperations with a cumulative incidence of reoperation 4.2% and development of moderate or greater aortic regurgitation was 7.3% [12]. In their midterm outcome report, Ozaki and colleagues pointed out that tricuspidization of the nontricuspid cases using preexisting commissures had been performed for 5.5 years, however, there were several cases in which the sizes of 3 cusps were very different, in which postoperative echocardiography showed uneven movements of the cusps [12]. Therefore tricuspidization is now being done with equal length of cusps, which was not done in our case. There is a lack in studiesincluding patients with small aortic annuli, younger patients and pediatric population. In a recent work by Del Nido et. Al, the Ozaki procedure demonstrated promising results even in children [19].

Aortic valve reconstruction with the Ozaki technique has shown several surgical benefits. Glutaraldehyde treatment provides more resistance against retraction and degeneration, and has been reported to maintainintrinsic tissue pliability of the pericardium. The tensile strength of glutaraldehyde-treated human pericardium was found to be 4 times greater than noncalcified leaflets, indicating its suitability for application to aortic valve reconstruction. The pericardium is sewn directly to the aortic annulus which maximises valve orifice area with physiologic transvalvular gradients. The contact point of the new pericardial cusps are raised up to the same plane of the commissures which increases the coaptation height [12]. Rosseykin et al reported that significantly lower values of the aortic valve pressure gradient and larger effective orifice area of the aortic valve were observed on postoperative echocardiography in patients with AVNeo compared with those with conventional bioprosthetic valves [20]. Yamamoto et al reported that aortic annular changes in patients with AVNeo were similar to those with normal aortic valves [21]. Absence of a stented frame preserves the physiological ability of aortic root to expand its diameter during systolic ejection, maintaining the natural coordination between left ventricle, aortic annulus, sinus of Valsalva, and the ascending aorta. Resuspending the three neocusps up to the level of the STJ provides an extensive coaptation area during diastole. This zone, known as effective height, is one of the most powerful predictors of the long-term valve competence. Since the Ozaki technique does not fix the aortic annulus, the neo-aortic annulus grows with time and a satisfactory coaptation surface present even when the annulus grows. Tricuspidization of a bicuspid or unicuspid valve with the Ozaki technique restores the typical

orientation of the cusps of a normal valve with appropriate length of the free margin of leaflets thereby permitting full opening while maintaining the normal valve shape. Aortic valve reconstruction in this manner can be done for any aortic valve disease- regurgitation, stenosis, infective endocarditis, and reoperation after bioprosthesis deterioration [12]. There is no need for warfarin postoperatively, and low-dose aspirin can be used for three to six months.In addition, this procedure can be mastered after a relatively short training period due to its high reproducibility and ease of learning all the steps required thanks to the significant standardization of the original surgical technique.

A customised technique was applied in our patient based on the Ozaki technique with custom made templates and calliperswith different cusp sizes, and a short 6 month follow up had a good result. CPB time was greater than a conventional valve replacement, however, patient outcome was quite satisfactory.

Conclusion

Aortic valve replacement with a prosthetic valve represents the gold standard to treat aortic valve diseases, but disadvantages are lifelong anticoagulation, thromboembolic events, device malfunction, spontaneous bleeding, re-operation, infection, and limited durability of the bioprostheses in children and young patients. Therefore, aortic valve reconstruction based on the Ozaki technique offers a prominent alternative solution in any aortic valve disease, specially in the younger population. Clinical trials and multicentre studies with large sample size and long term follow up is required for establishing this procedure as a standardised treatment for aortic valve disease.

References

1. Falk V., Baumgartner H., Bax J.J., De Bonis M., Hamm C., Holm P.J., et al. 2017 ESC/EACTS guidelines for the management of valvular heart disease. Eur J CardiothoracSurg. 2017;52:616-664.
2. Jaquiss R. Bioprosthetic aortic valve replacement in the young. Circulation. 2014;130:7-9.
3. Vahanian A., Alfieri O., Andreotti F., Antunes M.J., Baron-Esquivias G., Baumgartner H., et al. Guidelines on the management of valvular heart disease: the Joint Task Force on the Management of Valvular Heart Disease of the European Society of Cardiology (ESC) and the European Association for Cardio-Thoracic Surgery (EACTS) Eur J CardiothoracSurg. 2012;42(Suppl):S1-S44.
4. Hammermeister K., Sethi G.K., Henderson W.G., Grover F.L., Oprian C., Rahimtoola S.H. Outcomes 15 years after valve replacement with a mechanical versus a bioprosthetic valve: final report of the Veterans Affairs randomized trial. J Am Coll Cardiol. 2000;36:1152-1158.
5. Hill D.G. Long-term results of debridement valvotomy for calcific aortic stenosis. J ThoracCardiovascSurg. 1973;65:708-711.
6. Lillehei C.W., Gott V.L., De Wall R.A., Varco R.L. The surgical treatment of stenotic or regurgitant lesions of the mitral and aortic valves by direct vision utilizing a pump oxygenator. J ThoracCardiovascSurg. 1958;35:154-191.
7. Doss M., Sirat S., Risteski P., Martens S., Moritz A. Pericardial patch augmentation for repair of incompetent bicuspid aortic valves at midterm. Eur J CardiothoracSurg. 2008;33:881-884.

8. Odim J., Laks H., Allada Y., Child J., Wilson S., Gjertson D. Results of aortic valve sparing and restoration with autologous pericardial leaflet extension in congenital heart disease. Ann ThoracSurg. 2005;74:438-443.

9. Halees Z., Shahid M., Sanei A., Sallehuddin A., Duran C. Up to 16 years follow-up of aortic reconstruction with pericardium: a stentless readily available cheap valve. Eur J CardiothoracSurg. 2005;28:200-205.

10. Duran C.M.G., Alonso J., Gaite L., Alonso C., Cagigas J.C., Marce L., et al. Long-term results of conservative repair of rheumatic aortic valve insufficiency. Eur J CardiothoracSurg. 1988;2:217-223.

11. Ozaki S., Kawase I., Yamashita H., Uchida S., Nozawa Y., Matsuyama T., et al. Aortic valve reconstruction using self-developed aortic valve plasty system in aortic valve disease. Interact CardiovascThoracSurg. 2011;12:550-553.

12. Ozaki S., Kawase I., Yamashita H., Uchida S., Takatoh M., Kiyohara N. Midterm outcomes after aortic valve neocuspidization with glutaraldehyde-treated autologous pericardium. J ThoracCardiovascSurg. 2018;155:2379-2387.

13. Ozaki S., Kawase I., Yamashita H., Uchida S., Nozawa Y., Takatoh M., et al. A total of 404 cases of aortic valve reconstruction with glutaraldehyde-treated autologous pericardium. J ThoracCardiovascSurg. 2014;147:301-306.

14. Takahashi H., Kadowaki T., Maruo A., Yutaka O., Oshima Y. Mid-term results of mitral valve repair with autologous pericardium in pediatric patients. J Heart Valve Dis. 2014;23:302-309.

15. Komarov R., Chernov I., Enginoev S., Pompeu M.B., Tarasov D. The Russian conduit-combining Bentall and Ozaki procedures for concomitant ascending aorta replacement and aortic valve neocuspidization. Braz J CardiovascSurg. 2019;34:618-623.

16. Brewer R.J., Deck J.D., Capati B., Nolan S.P. The dynamic aortic root. Its role in aortic valve function. J ThoracCardiovascSurg. 1976;72:413-417.

17. Iida Y., Akiyama S., Shimura K., Fujii S., Hashimoto C., Mizuuchi S., et al. Comparison of aortic annulus dimensions after aortic valve neocuspidization with those of normal aortic valve using transthoracic echocardiography. Eur J CardiothoracSurg. 2018;54:1081-1084.

18. Ozaki S, Kawase I, Yamashita H, Uchida S, Nozawa Y, Takatoh M. A total of 404 cases of aortic valve reconstruction with glutaraldehyde-treated autologous pericardium. J Thorac. 2014;147(1):301-306.

19. Baird CW, Marathe SP, Del Nido PJ. Aortic valve neo-cuspidation using the Ozaki technique for acquired and congenital disease: where does this procedure currently stand? Indian J ThoracCardiovascSurg. 2020 Jan;36(Suppl 1):113-122. doi: 10.1007/s12055-019-00917-9.

20. Rosseykin EV, Bazylev VV, Batrakov PA, Karnakhin VA, Rastorguev AA. Immediate results of aortic valve reconstruction by using autologous pericardium (Ozaki procedure). Patolkrovoobrashchkardiokhir. 2016;20:44-8.

21. YamamotoY,IinoK,ShintaniY,KatoH,KimuraK,WatanabeG,etal.Comparison of aortic annulus dimension after aortic valve neocuspidization with valve replacement and normal valve. SeminThoracCardiovascSurg. 2017;29:143-9.

Primary Repair of Oesophagus in Three Difficult Scenario - A Case Series

Dr. Ritik Hooda; Dr. Jayita Chakraborty; Dr. Prakash Sanki; Dr. S.S. Mahapatra; Dr. Nabarun Mallik; Dr. Surajit Sarkar

Dept. of Cardiothoracic & Vascular Surgery, SSKM Hospital, IPGMER, Kolkata, West Bengal, India

ABSTRACT

Introduction: Perforation of Oesophagus results in chemical and infectious mediastinitis and pleuritis, which is dangerous to life unless treated early and effectively. The incidence of this complication is less than 0.05% during diagnostic endoscopy. However, it increases with the complexity of procedure and underlying oesophageal pathology. Upto 17% perforation rate has been documented after dilation of caustic strictures. And approximately 2% patients with achalasia treated with pneumatic dilation. This paper presents two cases of iatrogenic oesophageal perforations and one case of oesophageal foreign body removal that underwent primary repair in inflamed tissue and their management.

Observation: A total of three cases were included in the study. One female and two males. All cases had different pathophysiology, but all had chest X-ray and endoscopy report as preop diagnosis. All three cases underwent thoracotomy and primary closure of perforation site with tube drainage and feeding jejunostomy. Post op all three underwent gastrograffin study, and one patient had post op endoscopy to confirm no leak from suture site.

Conclusion: Oesophageal injuries are difficult to diagnose by primary survey investigation, but timely diagnosis and treatment can result in significant decrease in morbidity and mortality with good outcomes, if primary repair of oesophagus is permissible.

INTRODUCTION

- Perforation of Oesophagus results in chemical and infectious mediastinitis and pleuritis, which is dangerous to life unless treated early and effectively.
- Iatrogenic injury is the most common cause of perforation. [1]
- The incidence of this complication is less than 0.05% during diagnostic endoscopy. However, it increases with the complexity of procedure and underlying esophageal pathology.
- Upto 17% perforation rate has been documented after dilation of caustic strictures. And approximately 2% patients with achalasia treated with pneumatic dilation. [2,3,4,5]
- Trauma and spontaneous rupture are the next most common causes of perforation.
- This paper presents two cases of oesophageal perforations and one case of oesophageal foreign body with inflamed tissue that were referred to CTVS department IPGMER

Kolkata and their management.

Case Presentation

Case 1

A 36 years old female, known case of achalasia cardia underwent oesophageal dilation leading to perforation of lower oesophageal rupture diagnosed during endoscopy at the time of procedure and referred to CTVS department for emergency management.

- Presenting Symptoms - Left side chest pain
- Duration of Perforation - Within 24hours
- Preoperative Management -

1. Patient kept NPO.
2. IV Fluid and IV Antibiotics started.
3. Endoscopy and Chest X-ray (pneumothorax on left side) done to confirm diagnosis.
4. Left side Intercostal drainage tube inserted.

Operative Intervention -

1. Under GA with DLT, patient kept in right lateral position.
2. Left thoracotomy done via 5th intercostal space.
3. Oesophageal rupture of approx. 5cm found on left side in lower one- third of oesophagus.
4. Primary repair of oesophagus done using interrupted sutures in two layers.
5. Followed by myotomy downwards upto 3cm below diaphragm.
6. A feeding jejunostomy was done.

Post-Operative Management -

- Patient kept NPO with FJ feeding. Patient strictly observed for any signs of sepsis and post- operative leak with continuous drain output and content monitoring, serial blood investigations(CBC, CRP, S.Protiens).
- On tenth day, Gastrograffin study done. No leak found.
- Orally liquids followed by solid diet allowed.
- On twelfth day, ICDT removed followed by FJ removal after 3 weeks.
- Patient discharged on fourteenth day in good health.

Case 2

A 60 years old male was referred from gastroenterology department with right side chest pain, respiratory distress post endoscopic trial for foreign body removal. On investigations, patient was diagnosed with right side pleural effusion and pneumothorax on chest X-ray. On endoscopy, patient was diagnosed with oesophageal perforation.

Presenting Symptoms - Right side chest pain with respiratory distress.

Duration of Perforation - After 5 days

Preoperative Management -

1. Patient kept NPO.
2. IV Fluid and IV Antibiotics started.
3. CBC with WBC count 11,000 and Chest X-ray (pneumothorax and pleural effusion on right side with Right side ICDT) done.
4. Right side Intercostal drainage tube was already inserted on day of perforation.

Operative Intervention

1. Under GA with DLT, patient kept in left lateral position.
2. Right thoracotomy done via 5th intercostal space.
3. Oesophageal rupture of approx. 5 cm found on right side in lower one- third of oesophagus. A piece of meat was found just adjacent to the perforation site.
4. Primary repair of oesophagus done using interrupted sutures in two layers.
5. Followed by feeding jejunostomy.

Post-Operative Management -

1. Patient kept NPO with FJ feeding. Patient had low albumin, corrected with TPN initially, then after 3 days FJ feed with high protein diet started. Patient strictly observed for any signs of sepsis and post-operative leak.
2. On tenth day, Gastrograffin study done. Suspicion of leak found.
3. Endoscopy was done to confirm, no leak was found with healthy margin of sutured site.
4. Orally liquids followed by solid diet allowed.
5. On twelfth day, ICDT removed followed by FJ removal.
6. Patient discharged after 3 weeks.

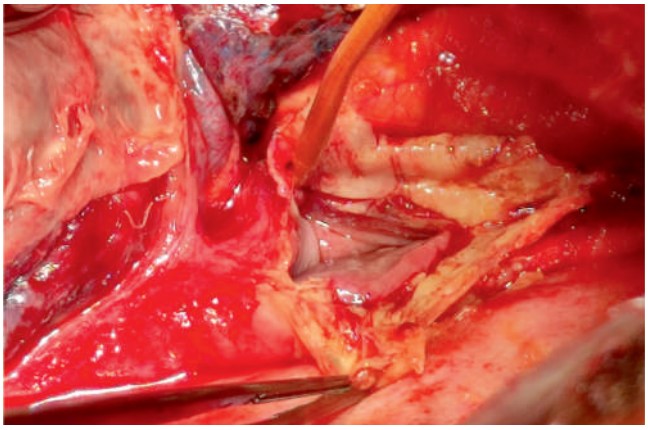

Perforation Site in Lower one third of Oesophagus

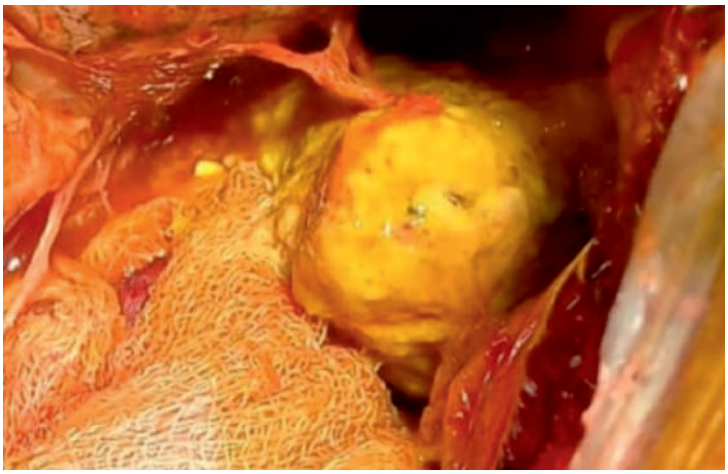

Meat Ball adjacent to perforation site

Case 3

A 70 years old male, referred from gastroenterology department with history of foreign body (denture) ingestion 25 days back with dysphagia to solid diet. Diagnosed at 35 cm from upper central incisors on endoscopy, five times the denture removal was attempted but failed. Consequently, the patient was referred to CTVS department for further management.

Presenting Symptoms - Dysphagia to solids post foreign body ingestion and chest pain.

Time of Foreign Body Ingestion - 25 days

Preoperative Management -

1. Patient kept NPO.
2. IV Fluid and IV Antibiotics started.
3. Endoscopy report and Chest X-ray confirmed the diagnosis.

Operative Intervention -

1. Under GA with DLT, patient kept in left lateral position.
2. Right thoracotomy done via 5th intercostal space.
3. Oesophagus was found inflamed with intact mucosa. An impacted denture was found inside the oesophageal cavity with small amount of localised pus inside lumen.
4. Denture was extracted and primary repair of oesophagus done using interrupted sutures in two layers, with intercostal muscle flap as reinforcement.
5. Followed by feeding jejunostomy.

Post-Operative Management -

1. Patient kept NPO with FJ feeding. Patient strictly observed for any signs of sepsis and post-operative leak.
2. On tenth day, Gastrograffin study done. No leak found.

3. Orally liquids followed by solid diet allowed.
4. On twelfth day, ICDT removed followed by FJ removal.
5. Patient discharged on fourteenth

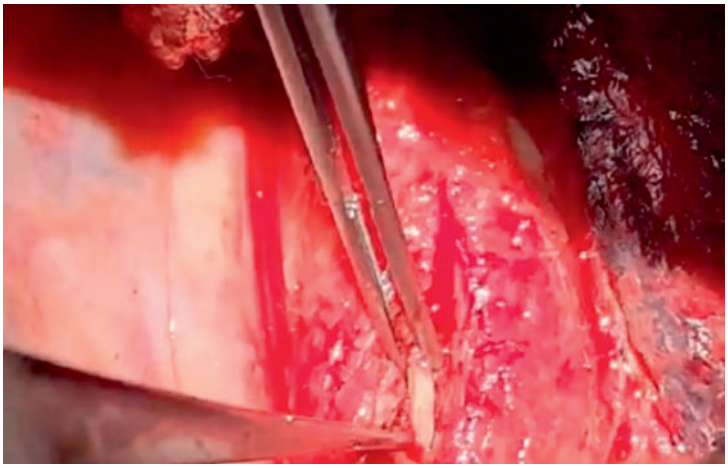

Site of inflamed oesophagus with denture in oesophageal cavity

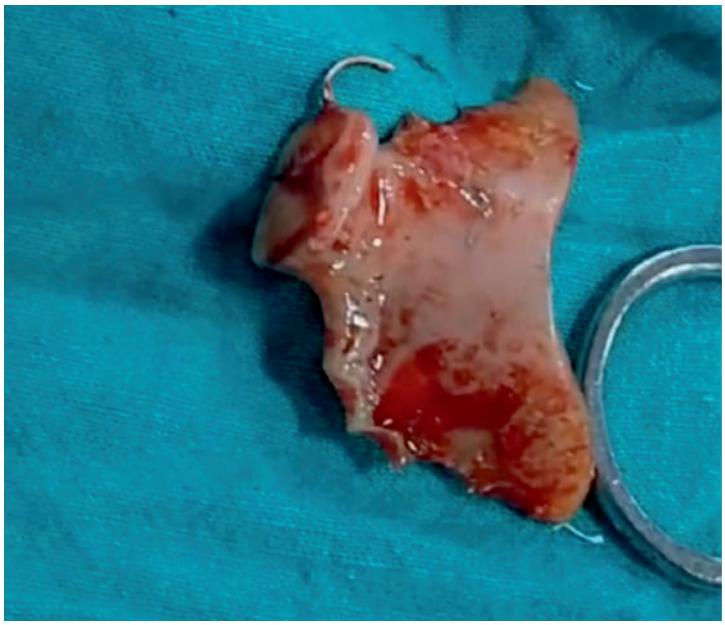

Denture extracted from oesophagus

DISCUSSION

- Patients with achalasia and other motor disorders must undergo a myotomy during perforation repair.
- Food bolus impaction is a common presentation in patients with Boerhaave syndrome.[6,7]

- Spontaneous ruptures are the most common cause of non-iatrogenic perforations, which result from a sudden increase in intra-oesophageal pressure, combined with negative intrathoracic pressure.
- Symptoms of spontaneous rupture are often non specific and include acute chest and abdominal pain, dyspnea and fever.
- Patient presenting with above symptoms after instrumentation of oesophagus must be considered a case of perforation until proved otherwise.
- A high index of suspicion is important for early recognition of injury.
- Foreign body impaction can be complicated by pressure necrosis, leading to wall ischemia in the affected segment and resulting in necrosis with subsequent perforations.
- Most ingested foreign bodies are seen in toddlers.[8]
- In younger adults, foreign body ingestion is usually associated with drug or alcohol abuse or psychiatric illnesses. In case of older adults, it is either dentures or any other Oesophageal pathology.
- Most small blunt objects can be removed using flexible oesophagoscope, surgical removal is rarely needed unless complicated by laceration or perforation.
- Pleural effusion, Pneumothorax, pneumomediastinum, and subcutaneous emphysema are non-specific chest X-ray findings.
- Definite diagnosis is made using CECT thorax and endoscopy.
- Endoscopic stenting to block perforations and prevent further contamination is accepted and is increasingly used nowadays.[9,10,11,12,13,14]
- Although Oesophageal stenting may not always spare patients from surgical intervention, but it offers less morbidity by decreasing contamination and early recovery.
- Oesophageal stenting is likely to be successful in cervical oesophagus, at Oesophago-gastric junction or in perforation longer than 6 cm. [15]

CONCLUSION

Esophageal perforation poses a significant challenge in diagnosis and treatment as these patients may present with a variety of nonspecific symptoms, such as abdominal, retrosternal chest pain, or vomiting and may also exhibit signs of sepsis and shock.

- Delayed recognition of a perforation makes successful primary repair less likely and result in high morbidity and mortality.
- The principles of surgical treatment are are debridement of devitalised tissue, treatment of underlying pathology, closure of perforation and drainage of cavity.
- A myotomy at the site of perforation provides better visualisation of the extent of damage to the mucosa and final repair of both layers is carried out.
- Reinforcement of repair can be done using various flaps (pleural, intercostal muscle), which provides better chances of wound healing, but should be taken from healthy site.

- Limitation of this study is less number of cases that presented to our department, further continuation of this study with larger patient data will be of more significance.

References

1. Jones WG, Ginsberg RJ: Esophageal perforation: a continuing challenge. Ann Thorac Surg 53(3):534-543, 1992.
2. Vaezi MF, Pandolfino JE, Vela MF: ACG clinical guideline: diagnosis and management of achalasia. Am J Gastroenterol 108(8):1238-1249, quiz 1250, 2013.
3. Kim JH, Song HY, Kim HC, et al: Corrosive esophageal strictures: long-term effectiveness of balloon dilation in 117 patients. J Vasc Interv Radiol 19(5):736-741, 2008.
4. Quine MA, Bell GD, McCloy RF, et al: Prospective audit of perforation rates following upper gastrointestinal endoscopy in two regions of England. Br J Surg 82(4):530-533, 1995.
5. Karnak I, Tanyel FC, Büyükpamukçu N: Esophageal perforations encountered during the dilation of caustic esophageal strictures. J Cardiovasc Surg (Torino) 39(3):373-377, 1998.
6. Spiegel A, Wolf DC, Sperber K, et al: An unusual presentation of eosinophilic esophagitis. Gastrointest Endosc 70(2):382-383, discussion 383, 2009.
7. Straumann A, Bussmann C, Zuber M, et al: Eosinophilic esophagitis: analysis of food impaction and perforation in 251 adolescent and adult patients. Clin Gastroenterol Hepatol 6(5):598-600, 2008.
8. Webb WA: Management of foreign bodies of the upper gastrointestinal tract. Gastroenterology 94(1):204-216, 1988.
9. Kuppusamy MK, Hubka M, Felisky CD, et al: Evolving manage- ment strategies in esophageal perforation: surgeons using nonop- erative techniques to improve outcomes. J Am Coll Surg 213(1):164-171, 2011.
10. Abbas G, Schuchert MJ, Pettiford BL, et al: Contemporaneous management of esophageal perforation. Surgery 146(4):749-755, 2009.
11. Keeling WB, Miller DL, Lam GT, et al: Low mortality after treatment for esophageal perforation: a single center experience. Ann Thorac Surg 90(5):1669-1673, 2010.
12. Freeman RK, Van Woerkom JM, Vyverberg A, et al: Esophageal stent placement for the treatment of spontaneous esophageal perforations. Ann Thorac Surg 88(1):194-198, 2009.
13. Dai Y, Chopra SS, Kneif S, et al: Management of esophageal anastomotic leaks, perforations and fistulae with self expanding plastic stents. J Thorac Cardiovasc Surg 141(5):1213-1217, 2011.
14. D'Cunha J, Rueth NM, Groth SS, et al: Esophageal stents for anastomotic leaks and perforations. J Thorac Cardiovasc Surg 142(1):39-46, 2011.
15. Freeman RK, Ascioti AJ, Giannini T, et al: Analysis of Unsuccess- ful Esophageal Stent Placements for Esophageal Perforation, Fistula, or Anastomotic Leak. Ann Thorac Surg 94(3):959-964, 2012.

Pulmonary thromboendarterectomies done in recent times in a tertiary care centre of eastern India: A case series

Surajit Sarkar[1], MS; S.S. Mahapatra[2], MCh; S. Dutta[3], MCh

1) MCh CTVS resident, Department of Cardiothoracic and Vascular Surgery, Institute of Post Graduate Medical Education and Research and SSKM Hospital, Kolkata
2) Professor, Department of Cardiothoracic and Vascular Surgery, Institute of Post Graduate Medical Education and Research and SSKM Hospital, Kolkata
3) Professor, Department of Cardiothoracic and Vascular Surgery, Institute of Post Graduate Medical Education and Research and SSKM Hospital, Kolkata

ABSTRACT

Purpose: To review the pulmonary thromboendarterectomies (PTE) in cases of Chronic thromboembolic pulmonary hypertension (CTEPH) done in our department with brief intermittent circulatory arrest.

Materials and methods: Data from 3 patients who underwent PTE for CTEPH between April 2021 and September 2023 in department of CTVS, IPGMER & SSKM Hospital are analysed retrospectively. Follow up was done clinically and by 2D Echocardiogram and computed tomography pulmonary angiogram (CTPA).

Results: All 3 patients had severe tricuspid regurgitation(TR) , and severe preoperative right ventricular(RV) dysfunction. 2 patients had diagnosed antiphospholipid antibody(APLA) syndrome. Thrombi were of Jamieson type III in 2 cases, and type I in one case. Median direct manometric mean pulmonary artery(PA) pressure decrease was from 48 mmHg to 22 mmHg. Median CPB time was 112 minutes, and median temperature 24°C. All 3 patients were extubated next day. There was no re-exploration and no mortality. Postoperative 2D Echocardiography revealed decreased median PA systolic pressures(76 mmHg vs 32 mmHg) and improved RV function by tricuspid annular plane systolic excursion(TAPSE)(median 12 mm vs 16 mm). Postoperative room air oxygen saturation also improved(median 57% vs 97%). In follow ups ranging between 1 and 30 months, all 3 patients returned to New York Heart Association (NYHA) Class I, with improved quality of life.

Conclusion & clinical significance: Operation for CTEPH can be done without profound hypothermia (18 °C) and circulatory arrest and side effects of these can be avoided.

INTRODUCTION

Complete Pulmonary thromboendarterectomy(PTE) is the definitive treatment of Chronic thromboembolic pulmonary hypertension (CTEPH)[1], and deep hypothermic circulatory arrest(DHCA) has been the most commonly employed technique to deal with bronchial back bleed, and obtain a bloodless field. However, prolonged DHCA has many adverse effects including neurologic deficits[2,3], renal dysfunction [4,5] and coagulopathy[6]. To avoid these complications, here we present our experience and outcome of intermittent circulatory arrest for

brief period of time in 3 patients with CTEPH.

METHODS

Study Design

No ethical clearance was needed as this was a retrospective case series. Data from 3 patients who underwent PTE for CTEPH between July 2021 and September 2023 in department of CTVS, IPGMER & SSKM Hospital are collected and analysed. Patients were followed up clinically and with 2D echocardiography (2D Echo) and computed tomography pulmonary angiogram (CTPA).

Inclusion criteria were patients with: 1) New york heart Association (NYHA) functional class III and IV symptoms; 2) thrombus in main, lobar or segmental pulmonary arteries(PA) as revealed in CTPA; 3) 2D Echo evidence of right ventricular (RV) dysfunction consequent to pulmonary artery hypertension (PAH).

Exclusion criteria included 1) patients with acute pulmonary embolism; patients without PAH or RV dysfunction; not fit to undergo cardiopulmonary bypass(CPB); and 2) cases of emergency pulmonary embolectomy.

Variables included demographic variables, pulmonary artery pressure (PAP)(Systolic, diastolic and mean), Central venous pressure(CVP), Oxygen saturation (Spo2), RV dysfunction by tricuspid annular plane systolic excursion (TAPSE), CPB time, location of thrombus by Jamieson's classification, postoperative course and complications.

Pre and postoperative echocardiogram gave pulmonary artery systolic pressure (PASP) and TAPSE. Intraoperative direct needle manometry of main pulmonary artery (MPA) before and after PTE gave respective PAP values. CVP and spo2 before and after PTE were also measured.

Patient details

Patient 1, a 23 year old lady with Primary Anti phospholipid antibody syndrome(APLA) presented to IPGMER with shortness of breath(SOB) and bipedal edema. Her CTPA showed complete occlusion of left PA(LPA) and subacute occlusion of posterobasal segmental branches of right lower lobe PA. She had consequent severe PAH, severe TR, RV failure and managed conservatively(Tablet Warfarin, Inj Enoxaparine, Tab Tadalafil). In January 2021, she developed RV failure induced hepatic dysfunction and Jaundice, room air saturation dipped to 57%. She underwent PTE in April, 2021.

Patient 2, a 38 year old obese lady attended IPGMER in January 2023 with SOB since the last 21 days. 2D Echo revealed high mean PAP(48 mm Hg). CTPA revealed subacute thrombosis in RPA extending into right lower lobar segmental branches. Treatment with Tab. Riociguat, Tab. Mecitentan and Inj. Heparin followed by Tab. Rivaroxaban provided no significant improvement with room air saturation dipping to 60%. The patient was put up for PTE in May 2023.

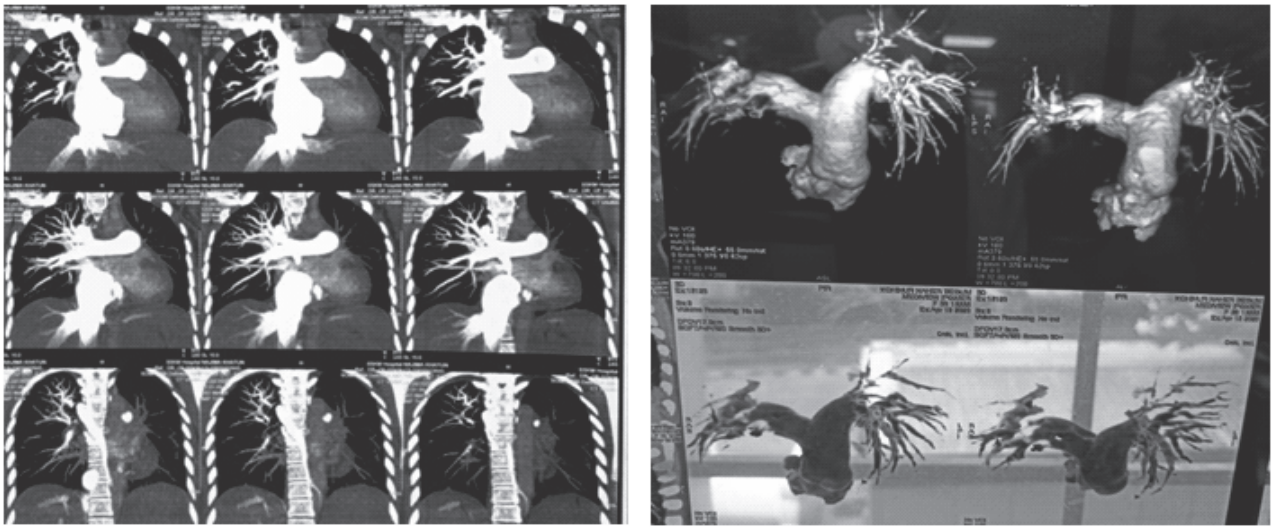

Fig 1: CTPA of patient 1 and 2

Patient 3, a 28 year old lady had recurrent deep venous thrombosis(DVT) and SOB since October 2022. On evaluation found to have APLA syndrome(March 2023). CTPA revealed near complete obstruction of RPA and branches. 2D Echo revealed severe PAH with mean PAP 54 mmHg and subsequent RV dysfunction. As room air saturation dipped to 54%, she was put up for PTE in August 2023.

Anesthetic Management

Along with General anaesthesia, inhaled nitric oxide was utilised to lower PAP. Monitoring was done by a radial and a femoral arterial line, central venous line, pulmonary arterial catheter, electrocardiography, nasopharyngeal temperature probe and transesophageal echocardiography (TEE).

CPB Pump Setup

We utilised a standard CPB circuit with Del nido cardioplegia, aortic and bicaval cannulation. Three pump suction lines, with one as a vent sucker for right upper pulmonary vein (RUPV) and other 2 free suckers were used. A hemoconcentrator for ultrafiltration was utilised. Core temperature was lowered to 24-28 °C(deep hypothermia) and flows were maintained at 2-2.4 l/min/m^2 with intermittent short term(3-5 minutes) circulatory arrest.

Surgical Technique

Median sternotomy, pericardiotomy, pericardial stay sutures were followed by direct pressure manometry by puncturing MPA. Aorta was dissected off MPA and RPA, and SVC is then looped and mobilized almost upto innominate vein confluence. By retracting both aorta and SVC away with vessel loops, intrapericardial mobilization of RPA and LPA was done upto the lower braches without opening the pleura.

CPB is entered via standard cannulation of ascending aorta and both vena cavae after heparinization. Root cardioplegia needle is inserted. Heart is stopped with Delnido cardioplegia, temperature lowered to 28 °C, and held there. A bullet cardiotomy suction is then used to vent RUPV.

In case of RPA THROMBUS, RPA is exposed between SVC and Aorta by mobilization using vessel loops and an arteriotomy is done. Since the RPA is filled with lumen shaped thrombus at this stage, there is not much back bleeding. Any fresh clot is removed to see the chronic thrombus. Next and most important step is the creation of correct plane of dissection, which appears as a smooth pearly white structure which can be peeled with controlled dissection by an olive tipped endarterectomy dissector. With the gradual development of this plane, the incision of RPA is extended upto the lower lobar branches, and this is aided by the movement and traction of aorta and SVC to right and left using vessel loops. Whole of RPA now lay open. The chronic thrombus is still in place, and temperature is held at 28 °C. Now the thrombus is gradually taken out, and openings of the branch PA starts being visualized. Back bleed also started, and to clear the field, temperature is lowered to 24 °C, and flow lowered to 1-1.2 l/min/m², at which, field can be cleared with 2 cardiotomy suctions. Circulatory arrest was only needed for a brief period of 3-4 minutes to clear the sublobar branches. While doing so, traction and dissection of thrombus evert the media, and may cause PA perforation. Gentle extraction of the thrombus ensures en masse removal(Fig 2).

Afterwards, gentle positive pressure ventilation is needed to check for leaks in PA wall, which appear as air bubbles in the operating field. Brisk bright red back bleed indicates complete clearance. Pulmonary arteriotomy repair started at distalmost angle, and after taking few sutures, flow was re-established. Rest of RPA was then closed in two layers with running 5-0 polypropelene sutures(Fig 2).

In case of LPA THROMBUS, an incision is made in the MPA and extended into the LPA beyond the origin of the upper lobe artery. Rest of the steps are same as discussed above for RPA.

Temperature was raised and patient weaned off CPB gradually, direct PA pressure manometry was done, and chest was closed after hemostasis.



Fig 2: RPA clearance and repair, with endarterectomy specimen of all 3 patients (First One LPA, rest 2 RPA)

RESULTS

Total 3 patients were operated for CTEPH from April 2021 to August 2023. All 3 patients were extubated the next day with median ventilation time being 24.5 hours. There was no mortality. In follow ups ranging between 1 and 30 months, all 3 patients reported significant improvement in quality of life, and returned to New York Heart Association (NYHA) Class I. There were no neurologic complications.

Table 1 summarises the results with all different data and values.

Table 1: Perioperative details of patients undergoing PTE

PREOPERATIVE FINDINGS:

1) Demography:

	Patient 1	**Patient 2**	**Patient 3**	**Median**
Age(years)	23	38	28	28
Sex	Female	Female	Female	
Preoperative ICU admission	Yes	Yes	Yes	
DVT	No	No	Yes	
NYHA Class	IV	IV	III	
Diagnosis	APLA Syndrome	Idiopathic	APLA Syndrome	

2) 2D Echo:

EF(%)	58	62	68	62
PASP(mm Hg)	69	82	74	74
TR	Severe	Severe	Severe	
TAPSE(mm)	12	10	14	12

3) Preoperative CTPA

RPA(mm)	17	22	21	
LPA(mm)	20	21	19	
MPA(mm)	29	32	31.5	

INTRAOPERATIVE FINDINGS:

Jamieson class	III	I	III	
CPB Time(Minutes)	112	120	108	112
Minimum temp(°C)	24	24	24	24

SpO2(%)

Preoperative	57	60	54	57
Postoperative	97	96	98	97

CVP

Preoperative	23	25	22	23
Postoperative	13	13	12	13

ABP (systolic/diastolic/Mean in mmHg)

Preoperative	98/60/73	145/110/122	74/49/57	MAP 73
Postoperative	118/82/94	106/62/77	116/69/85	MAP 71

PAP(Systolic/diastolic/Mean in mmHg)

Preoperative	69/34/45	82/32/48	74/38/54	mPAP 48
Postoperative	35/20/25	32/20/22	28/17/21	mPAP 22

POSTOPERATIVE FINDINGS

1) ICU Parameters:

Re-Exploration	No	No	No	
Ventilation(hours)	22	28	24.5	24.5
ICU Stay(days)	*10.5*	*18*	8	10.5
Department Stay(days)	17	20	14	17
NYHA Class	I	*I*	*I*	

2) 2D Echo:

EF(%)	60	64	68	64
PASP(mm Hg)	30	40	32	32
TR	Mild	Mild	Trace	
TAPSE(mm)	16	14	18	16

3) Postoperative CTPA:

RPA, mm	16	20	20	
LPA, mm	18	18	18	
MPA,mm	26	28	30	

4) Follow up (months)

	30	6	1	6

DISCUSSION

PTE is the definitive treatment of CTEPH[1]. Good outcome in PTE depends largely on the complete clearance of organised thrombus [8].

Literature has extensive description of the use of long term DHCA in the conduct of PTE and the side effects thereof [2-6]. Different strategies to limit the use of DHCA and its side effects have also been described.

In our simple modification, temperature is lowered to and held at 28°C during dissection of chronic thrombus, which itself prevents back bleed. After completion of dissection, temperature is lowered furthur as the thrombus is being pulled out. The flow is kept at 1-1.2 l/min/m², and managed by cardiotomy suctions. During subsegmental bronchi thrombus dissection, circulatory arrest for 3-4 minutes has to be done at 24 °C to complete the remaining endarterectomy.

Division of the great vessels was avoided, thus minimizing vascular trauma[9]. Due to the minimal time in circulatory arrest, the need of complex cannulation of the aortic arch vessels for selective antegrade cerebral perfusion(ACP) is negated[1-10].

These modifications allowed us to minimise the adverse effects of long term DHCA, while maintaining a relatively bloodless field, allowing complete clearance of the Pas.

LIMITATIONS:

The following limitations remain:

1) The sample size is too small to obtain statistically significant results.
2) The retrospective nature of the study itself is a limitation and a hindrance to obtain extensive set of data despite best efforts.

CONCLUSION AND CLINICAL SIGNIFICANCE:

With advances in operative and perfusion strategies, PTE does not need longer total circulatory arrest and profound hypothermia(18 °C) and the related side effects of these can be avoided. However, the present study contains too few cases to establish the advantages of our technique. Our future endeavors in this line will continue with that goal in mind.

REFERENCES:

1. Jamieson SW, Kapelanski DP, Sakakibara N, Manecke GR, Thistlethwaite PA, Kerr KM, et al. Pulmonary endarterectomy: experience and lessons learned in 1,500 cases. Ann Thorac Surg. 2003;76(5):1457-62; discussion 1462-4. doi:10.1016/s00034975(03)00828-2.
2. Kamenskaya OV, Cherniavsky AM, Klinkova AS, Cherniavsky MA, Meshkov IO, Lomivorotov VV, et al. Efficiency of various cerebral protection techniques used during the surgical treatment of chronic pulmonary thromboembolism. J Extra Corpor Technol. 2015;47(2):95-102.
3. Tian Tian DH, Wan B, Bannon PG, Misfeld M, LeMaire SA, Kazui T, et al. A meta-analysis of deep hypothermic circulatory arrest versus moderate hypothermic circulatory arrest with selective antegrade cerebral perfusion. Ann Cardiothorac Surg. 2013;2(2):148-58. doi:10.3978/j.issn.2225-319X.2013.03.13.
4. Yu L, Gu T, Zhang G, Cheng S, Fang Q, Mao N. The deep hypothermic circulatory arrest causes more kidney malfunctions based on a novel rabbit model. Ann Saudi Med. 2014;34(6):532-40. doi:10.5144/0256-4947.2014.532.
5. Zhang C, Wang G, Zhou H, Lei G, Yang L, Fang Z, et al. Preoperative platelet count, preoperative hemoglobin concentration and deep hypothermic circulatory arrest duration are risk factors for acute kidney injury after pulmonary endarterectomy: a retrospective cohort study. J Cardiothorac Surg. 2019;14(1):220.

6. Mazzeffi M, Marotta M, Lin HM, Fischer G. Duration of deep hypothermia during aortic surgery and the risk of perioperative blood transfusion. Ann Card Anaesth. 2012;15(4):266-73.

7. Jenkins D, Madani M, Fadel E, D'Armini AM, Mayer E. Pulmonary endarterectomy in the management of chronic thromboembolic pulmonary hypertension. Eur Respir Rev. 2017;26(143):160111. doi:10.1183/16000617.0111-2016.

8. Sakurai Y, Takami Y, Amano K, Higuchi Y, Akita K, Noda M, et al. Predictors of outcomes after surgery for chronic thromboembolic pulmonary hypertension. Ann Thorac Surg. 2019;108(4):1154-61. doi:10.1016/j.athoracsur.2019.03.100.

9. Jamieson SW. Historical perspective: surgery for chronic thromboembolic disease. Semin Thorac Cardiovasc Surg. 2006;18(3):218-22. doi:10.1053/j.semtcvs.2006.09.007.

10. Masuda M, Mogi K, Nakaya M, Pearce Y, Imamaki M, Shimura H, et al. Surgical treatment for chronic pulmonary thromboembolism under cardiopulmonary bypass with selective cerebral perfusion. Surg Today. 2001;31(2):108-12.

Management and outcomes of tracheal stenosis- pre and post COVID era- our experience

Unmesh Chakraborty

ABSTRACT

INTRODUCTION

Tracheal stenosis, is an emergency, commonly precipitated by prior intubation which although is a life-saving procedure, but may cause mucosal damage and tracheal wall necrosis, which eads to laryngo-tracheal stenosis.

The pathogenesis of post- intubation tracheal stenosis is considered to be a byproduct of impaired healing process involving mucosal inflammation, local hypoxia, biomechanical stress and resultant dysregulated tissue repair.

There is no statistical evidence yet about the rate of laryngotracheal stenosis or even post intubation stenosis in post- Covid 19 patients even though it has been thought to be higher, in some studies, compared to non-COVID 19 patients where the rate varies from 10 to 22%. This is likely due to the sustained hyperinflammatory state causing altered fibrosis along with dysregulated tissue repair.

PATIENTS AND METHODS

A total of 26 patients, from January 2017 till October 2023, were retrospectively reviewed, in this study. This included 16 patients who underwent surgery via tracheal resection and reconstruction. Four underwent balloon dilatation, 2 had tracheal stenting, while the remaining 4 had tracheostomy with placement of Montgomery T tube. Out of 26, 10 patients had a history of prior intubation as their primary etiology.

We divided these 26 patients into two groups, A and B. Group A had 7 patients who had suffered from COVID 19. 4 of them had mild COVID, whereas 3 of them had severe COVID needing prolonged hospital admission and respiratory support. Group B had 19 patients, who had no history of COVID 19. 5 of them had prior history of intubation, while 12 were due to mass effect. Demographic variables, presenting complaints, symptom evaluation, surgery done and postoperative course with followup was compared for both groups. Mean values were calculated, and percentages expressed as compared between groups, via level of significance seen, by Fisher's exact test.

RESULTS

Both the groups were comparable and had no difference with respect to age, gender distribution, mean number of days admitted in hospital, smoking history. Both groups had fivepatients each with a history of prior intubation, and while one of the patients in Group A had a history of prior tracheostomy, it was present in 2 patients in Group B. There was no statistically significant difference between the groups when it came to evidence of stridor, hoarseness of voice and

saturation in room air. Dyspnea, classified according to mMRC scale, was comparable as well, although mMRC grade 4 was more in percentage, in Group A. Severity of stenosis, via Cotton Meyer grading, also did not reveal any statistically significant

difference.Grade 4 severity was present in 71.42% of Group A, and 47.36% of Group B. Surgery was performed for 5 patients in Group A and 11 patients in group B. Postoperative course was similar in noth groups. There was evidence of air leak in one patient each per group. While 1 patient in Group A had granuloma formation, the number of the same in Group B was 2. There was no recurrent laryngeal nerve paresis or palsy, and glottic dysfunction or tracheoinnominate fistula in either group.One patient in Group B had infection, which resolved. Two patients in Group B needed reintervention, while one patient in Group A needed so, that too, multiple

times, finally undergoing a stenting, on the 4th instance. There was no statistically significant difference when it came to postoperative events, imaging findings on follow-up and evidence of symptomatic relief. There was no perioperative mortality. One patient, from Group B, passed away due to a non related cause, in the followup period. All the other patients have been routinely followed up, and are doing well, with no functional limitations and healthy current general condition.

DISCUSSION

Optimal mode of investigations and management needs to be customized for every case and depending on the level and extent of stenosis, intervention may include endoscopic dilatation, stenting, laser surgery, steroid injection, cryosurgery or open surgery involving resection and repair with grafts or end-to-end anastomosis.

Tracheal resection and anastomosis remains the gold standard treatment, but the restenosis rates in such operated cases is variable, and can be around 9.5% to 61%, and was probably assigned to causes like tensions anastomosis, devascularization of the anastomosis area due to wide dissection along with resection of long segment of trachea

Evidence of severity of stenosis, and dyspnea, were more in Group A, comprising of COVID patients. Total number of re-interventions were also higher in the group. Although not statistically significant, yet, one can presume that COVID 19 certainly adds to the burden of tracheal stenosis in such instances.

Our limitations were, lack of large pool of patients, heterogenous disease identity and lack of single modality of treatment. Long term followup is also desirable.

CONCLUSION

Even after a few years of the COVID 19 pandemic, incidence of tracheal stenosis and other complications have not stopped. When a COVID-19 patient who had been intubated before, complains of chronic cough or dysphagia and has some evidence of stridor and dyspnea, later on after discharge, post-intubation tracheal stenosis should be suspected and thoroughlyinvestigated. This also raises the question of well-equipped units specializing in airway surgery being adept in handling such burden. In the post-surgery phase, due to the possible high number of re-interventions required in these patients, close follow up is of utmost necessity. All said and done, prevention of tracheal stenosis in acute care settings is of paramount importance.

VATS in emergency and traumatic thoracic surgery- our change in practice

Subhendusekhar Mahapatra*, Prakash Sanki, Nabarun Mallick*****

**Professor, Dept. of CTVS, IPGMER & SSKM*
*** Head and Professor, Dept. of CTVS, IPGMER & SSKM*
****PDT, Dept. of CTVS, IPGMER & SSKM*

Introduction

VATS has revolutionized the surgical management of thoracic diseases in last two decades. In many thoracic diseases VATS is now regarded as the procedure of choice. Less postoperative stay, less pain, better cosmesis have proven VATS a feasible option in various elective thoracic surgeries.

In our set up VATS has been an ongoing programme since 2007. But over last year we have introduced VATS in traumatic and emergency surgery as well. Various studies have shown comparative results with VATS in traumatic hemothorax and other traumatic thoracic condition.

Our aim in this study is to evaluate if VATS has any added advantages over current conservative and delayed management of traumatic hemothorax and other traumatic chest condition.

Aim

Comparative study between delayed exploration of traumatic hemothorax with or without associated rib fractures and vats guided immediate exploration within one week.

Procedure

All the patients who come to trauma emergency with c/o chest trauma undergo chest x-ray following initial resuscitation and are referred to CTVS emergency for further management. When indicated intercostal chest drain is put in the affected pleural cavity and CT scan of thorax is advised after 72 hours. The patients are reviewed again after CT scan and assessed for further management. If the patient is symptom free and without any distress then irrespective of the CT scan result they are advised for conservative management with respiratory physiotherapy and repositioning of chest drain, pain management. Over last one year following daily application of VATS we have taken few such cases for VATS guided lavage and adhesiolysis based on retained hemothorax and CT findings. For the study purpose the whole population was randomly divided into two groups, one who were treated with current conservative management and the other who were treated with VATS exploration and lavage.

Conservative management: patients were advised for respiratory physiotherapy, pain management, antibiotics therapy, drain repositioning and they were serially followed up for spontaneous resolution of hemothorax or lung expansion following which ICD could be removed. Upon removal ICD they were discharged and further follow up was done on outdoor basis after 2

weeks, 1 month and 3 months VATS procedure: patient was positioned in lateral decubitus with affected side being upwards. First entry port was done through the ICD site. Later the ICD port was extended upto 3-4 cm as utility port and after clearing the area near diaphragm one additional camera port was made at 9th ICS at mid axillary line. Complete adhesiolysis was done with blunt and sharp dissection, all clots were removed, lung was thoroughly inspected and any significant laceration or air leak was repaired. Any rib fractured segment which needed to be fixed were marked over skin under direct vision. After completion of VATS procedure, skin incision was made directly over the marked area and ribs were fixed with stainless steel wires. Adhesiolysis and lavage was done till adequate lung expansion was visible. Any air leaks of more than 150 ml wererepaired. While closing the chest one ICD was given through the camera port. Post op follow up was done and patient was discharged after ICD being removed. Patients were similarly followed up in OPD at 2 weeks, 1 month and 3 months.

Inclusion criteria for VATS

1) Any retained hemothorax after 72 hours of putting icd and within 1 week of trauma.
2) No primary lung disease
3) Patient is able to undergo general anesthesia
4) Indicated rib fixation
5) Hemodynamically stable

Data collection: retrospective data was collected from OT registrar, bed head tickets, discharge summaries.

Following parameters were reviewed: hospital stay, pain score, duration of ICD, operative time, serial monitoring of x-ray to look for expansion of lung.

Results

Total 48 cases were included in this study. The whole population was divided into two sub group randomly. One group was managed conservatively and the other group was treated with VATS exploration.

Parameters	VATS exploration	Conservative managements
Mean operative time	46 minutes	-
Mean hospital stay	4 days	7 days
Removal of ICD (mean)	3 dyas	6 days
Duration for complete expansion of lung	6 days	21 days
Restriction of life style on 1 month follow up	3	8
Pneumonia	3	3
others	Conversion to open- nil Persistent air leaks beyond 1 week- 2 Redo surgery- nil	Delayed decortication -5 Partial resolution without any symptoms- 4

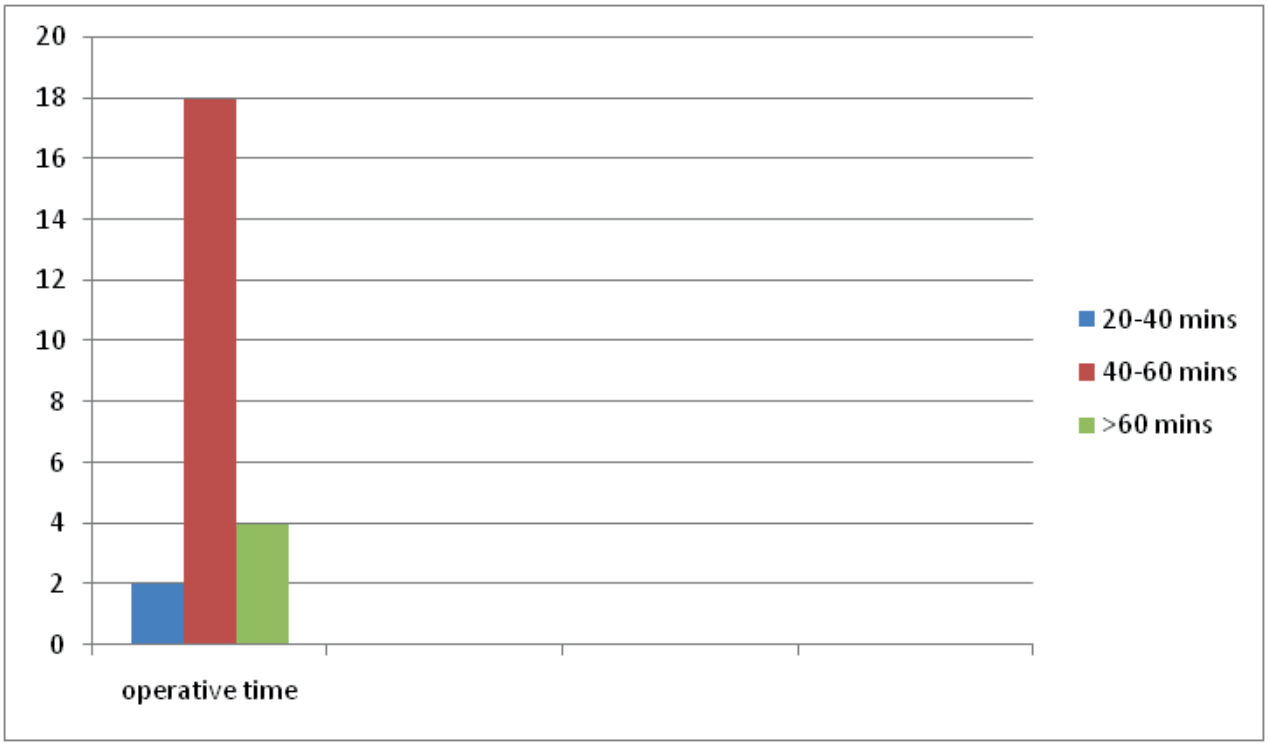

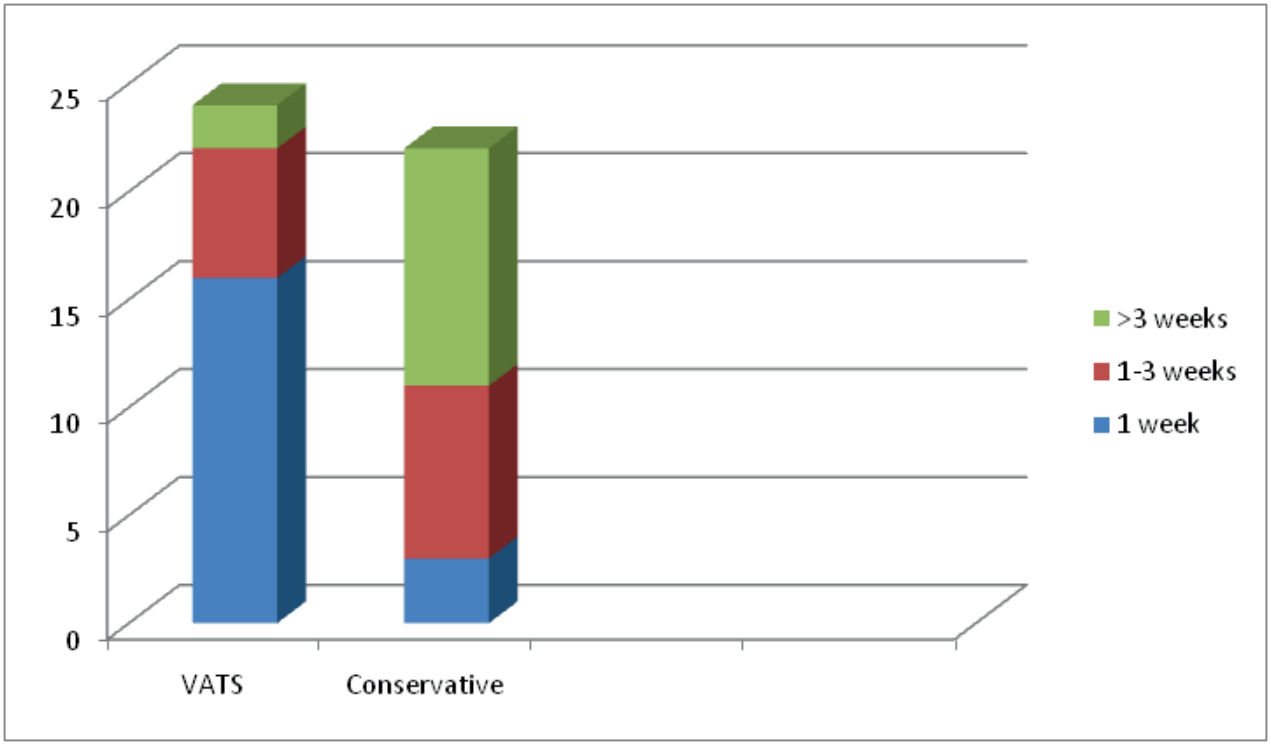

Duration for complete lung expansion

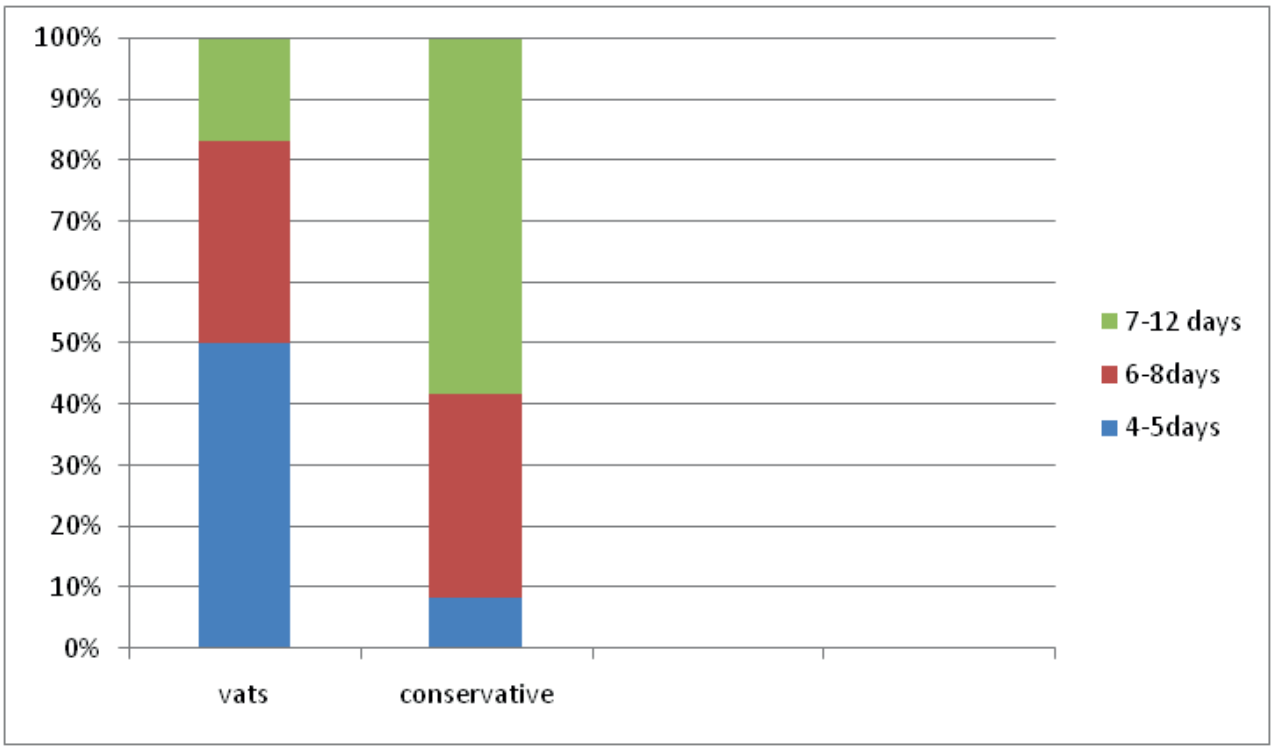

Hospital stay

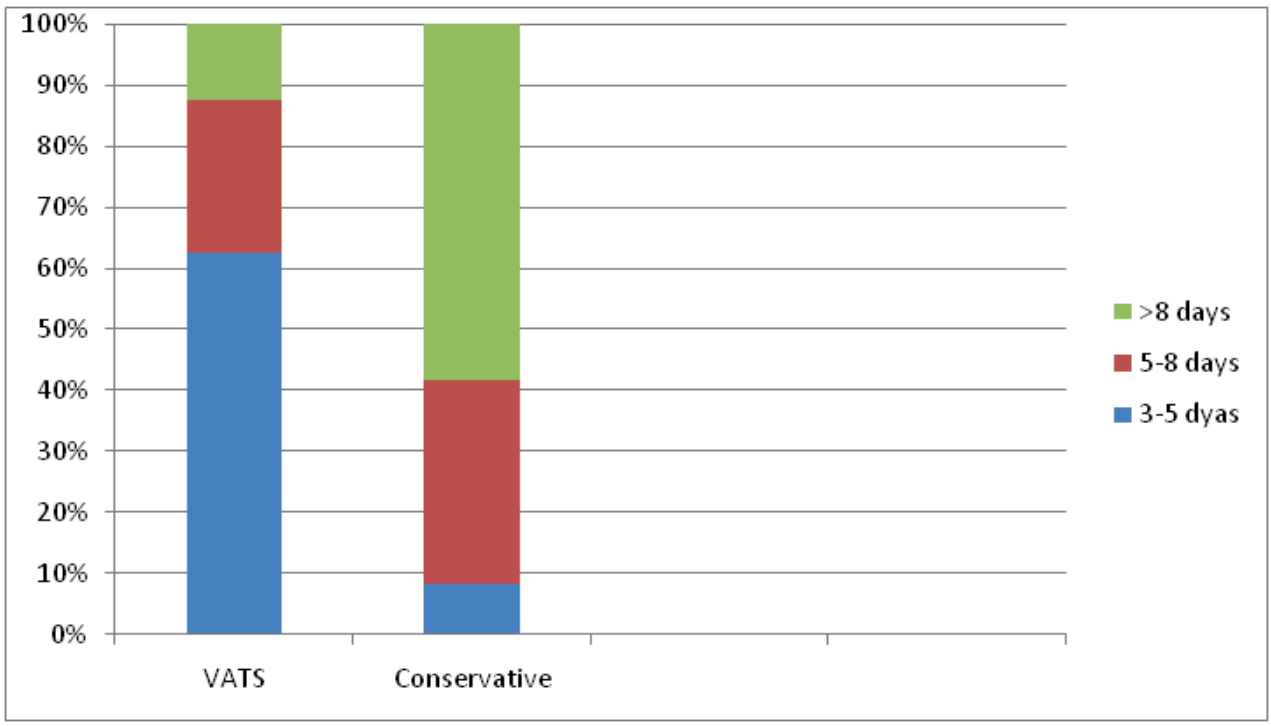

ICD removal

Salient findings and Discussion

Blunt trauma chest has its various complications such as, retained hemothorax, respiratory failure, and empyema. A retained hemothorax is defined as persistence of residual clots in the pleural cavity evident in radiological investigation after 72 hours. Various studies have shown improved outcome in such cases over conservative managements. Early intervention within 72-96 hours has more favourable outcome than delayed intervention. Early intervention also negates the chance of fibrosis and empyema formation.

Our study has shown that intervention within 72-96 hours significantly reduces operative time and difficulty. As the duration from trauma increases adhesion between parietal and visceral pleura gets thickened and fibrosed.

In case of associated rib fractures or lung laceration, vats provides significant operative advantage over open surgery

Patients who were treated with VATS had early complete expansion of lung field. Requirement of ventilator support was less. Total duration of hospital stay was significantly less.

Patients who were treated with conservative management had prolonged hospital stay, restricted life style and significant prolonged time for complete expansion of lung field.

Conclusion

Early intervention in the means of VATS can be a beneficial and preferred modality of choice in case of blunt trauma chest with stable vitals.

References

1) odhia JV, Konstantinidis K, Papagiannopoulos K. Video-assisted thoracoscopic surgery in trauma: pros and cons. J Thorac Dis. 2019 Apr;11(4):1662-1667. doi: 10.21037/jtd.2019.03.55. PMID: 31179111; PMCID: PMC6531729.

2) Goodman M, Lewis J, Guitron J, Reed M, Pritts T, Starnes S. Video-assisted thoracoscopic surgery for acute thoracic trauma. J Emerg Trauma Shock. 2013 Apr;6(2):106-9. doi: 10.4103/0974-2700.110757. PMID: 23723618; PMCID: PMC3665056.

3) A.V. Manlulu, T.W. Lee, K.H. Thung, R. Wong, A.P.C. Yim, Current indications and results of VATS in the evaluation and management of hemodynamically stable thoracic injuries, European Journal of Cardio-Thoracic Surgery, Volume 25, Issue 6, June 2004, Pages 1048-1053.

4) Hsing-Lin Lin, Wen-Yen Huang, Chyan Yang, Shih-Min Chou, Hsin-I. Chiang, Liang-Chi Kuo, Tsung-Ying Lin, Yi-Pin Chou, How early should VATS be performed for retained haemothorax in blunt chest trauma?,Injury,Volume 45, Issue 9,2014,Pages 1359-1364,ISSN 0020-1383.

5) Apaydin T. The Role of Minimally Invasive Surgery in Management of Chest Trauma [Internet]. Trauma and Emergency Surgery. IntechOpen; 2022. Available from: http://dx.doi.org/10.5772/intechopen.98439.

An innovative approach to subclavian steal syndrome: Aorto-axillary bypass

Swanand Khapli[1] MBBS, Dhiraj Barman[1] MCh, Kaushik Sundar[2], Lalit Kapoor[1] Mch

1-Department of Cardiac Surgery, NH Rabindranath Tagore International Institute of Cardiac Sciences, Kolkata, India

2-Department of Cardiac Surgery, NH Rabindranath Tagore International Institute of Cardiac Sciences, Kolkata, India

Introduction

Subclavian steal syndrome (SSS) is a medical condition that arises from retrograde blood flow in the vertebral artery or the internal thoracic artery due to proximal stenosis (narrowing) and/or occlusion of the main subclavian artery during arm activity. We present an innovative surgical technique to approach SSS which has not been explained before.

Case presentation

A 56 year old gentleman presented with hemiparesis on the left side with recurring episodes of syncope after working with the right arm since 7 days. He was a known hypertensive, diabetic, and active smoker with a pack-year index of 25. Digital Subtraction Angiography (DSA) showed complete occlusion of right common carotid artery, both of its branches, the right subclavian artery, mild stenosis of left subclavian artery and also showed the steal of blood flow from vertebral circulation. An aorto-subclavian bypass was planned. We first tried to access the subclavian artery in the supraclavicular area, but the subclavian artery was found very narrow and chord-like. Hence the axillary artery was approached in the deltopectoral groove and the 8-mm Intering PTFE vascular graft was anastomosed between the ascending aorta and axillary artery. Pre grafting, the radial artery pressure was 88/60(69) mmHg, and simultaneous femoral artery pressure was 161/73(102) mmHg. Post-aorto-axillary bypass both pressures were the same. Postoperative DSA showed no residual steal and good flow from aorta to right axillary artery. Postoperatively the patient improved symptomatically and living normal life.

Discussion

For individuals who are of low surgical risk and have symptoms of subclavian steal syndrome, open surgery has been advised as the initial course of treatment. Long-term primary patency was significantly higher after surgical repair as per previous studies.[(1)] If the vertebral artery gets adequate antegrade blood flow from the subclavian artery, then vertebral steal would not persist. Surgical options for subclavian steal syndrome are carotid-right subclavian bypass(CSBG), aorto-right subclavian bypass, left subclavian- right subclavian bypass, aorto-brachiocephalic-left common carotid artery bypass and left subclavian artery transposition.[(2)] CSBG being the most frequent procedures followed by axillo-axillary bypass in SSS. In our case carotid artery was completely occluded and mild stenosis was present on left subclavian artery

hence both these options were ruled out. Hence, an aorto-subclavian bypass was planned. For the choice of graft, there was no difference in the patency of the Dacron and PTFE grafts at long-term as per literature. Hence we used PTFE graft.[2]

Conclusion

In conclusion, patients who have occlusion of subclavian and carotid artery stenosis, aorto-axillary bypass should be used as a alternative in selected cases though long term results are awaited.

Reference

1. Galyfos GC, Kakisis I, Maltezos C, Geroulakos G. Open versus endovascular treatment of subclavian artery atherosclerotic disease. Journal of Vascular Surgery. 2019 Jan 1;69(1):269-79.
2. Ozen A, Unal EU, Kubat E, Caliskan A, Soran B, Kiris E, Aksoyek A, Birincioglu CL. Surgical procedures in subclavian steal syndrome: A retrospective analysis. Journal of cardiovascular surgery. 2015;3:4-7.

List of Doctors' Full Members

Sl. No.	Type	Memb. No.	Status	First Name	Last Name	Mobile	Email
1	LM	L/01/1998	Dr	Subhankar	Bhattacharya	9830151558	dr_sbctvs@rediffmail.com
2	LM	L/02/1998	Dr	Himansu Kumar	Dasmahapatra	9830041429	hkdasmahapatra@hotmail.com, hkdasmahapatra@gmail.com
3	LM	L/03/1998	Dr	Kunal	Sarkar	9830080006	kunal.cardiac@mail.com
4	LM	L/04/1998	Dr	Pares	Bandyopadhyay	9433099617	pares_bandyopadhyay@yahoo.co.in
5	LM	L/05/1998	Dr	Uttam Kumar	Mukhopadhyay	9830049035	uttammukherjee11@yahoo.com
8	LM	L/08/1998	Dr	Ashis	Mandal	9433204189	ashismandal1980@gmail.com
9	LM	L/09/1998	Dr	Plaban	Mukherjee	9830007503	plaban999@rediffmail.com
10	LM	L/10/1998	Dr	Gautam	Sengupta	9830234107	gsengupta56@gmail.com
13	LM	L/13/1998	Dr	Sachinandan	Banerjee	9831095111	sachinandan@rediffmail.com
14	LM	L/14/1998	Dr	Bhabatosh	Biswas	9831021617	bhabatos@yahoo.co.in, bhabatos@gmail.com
15	LM	L/15/1998	Dr	Siddhartha	Mukhopadhyay	9339779468	dr_sidm@yahoo.com
16	LM	L/16/1998	Dr	Ganes Chandra	Ray	9830071490	ganes_ray@yahoo.co.in
21	LM	L/21/1998	Dr	Debabrata	Mittra	9831086175	mittrad@gmail.com
22	LM	L/22/1998	Dr	Susheela	Mittra	9831801122	mittrad@gmail.com
23	LM	L/23/1998	Dr	Barun Chandra	Roy	9831091954	barunchandra_roy@yahoo.com
24	LM	L/24/1998	Dr	Srirup	Chatterjee	9830041378	srirup@vsnl.net.in
25	LM	L/25/1998	Dr	Satyajit	Bose	9830023695	s.bose@vsnl.com, drsatyajit@man.com
26	LM	L/26/1998	Dr	Ashok	Bandyopadhyay	9830030503	
27	AM	A/27/1998	Dr	Mayukh	Chatterjee		mayukhchat@yahoo.co.uk
28	LM	L/28/1998	Dr	Sushan	Mukhopadhyay	9830030509	drsushan1964@hotmail.com, drsushanmukho@hotmail.com
30	LM	L/30/1998	Dr	Lalit	Kapoor	9874523000	drlalitkapoor@gmail.com, lolly@cal.vsnl.net.in

Sl. No.	Type	Memb. No.	Status	First Name	Last Name	Mobile	Email
32	LM	L/32/1999	Dr	Uday Narayan	Sarkar	9830059128	drudaysarkar@yahoo.com
33	LM	L/33/1999	Dr	Kallol	Dasbaksi	9830321432	kalloldb@yahoo.com
35	AL	A/35/1999	Dr	Dibakar	Das	9432226064	dbkrdas@gmail.com
36	LM	L/36/1999	Dr	Anjan Kumar	Das	9831086359	
37	AM	A/37/1999	Dr	Saikat Debiprasad	Sengupta	9830179539	
40	AM	A/40/1999	Mr	Sudhakar J	Rao	9831345057	sudhaxg@gmail.com
44	LM	L/44/1999	Dr	Chandan Kumar	Saha	9433123799	csaha15@gmail.com
46	LM	L/46/1999	Dr	Mrinal Bandhu	Das	9831010985	krishnakoli@yahoo.co.in
48	LM	L/48/1999	Dr	Tapas	Raychaudhuy	9830029041	tapasrc@gmail.com
50	AM	A/50/1999	Dr(Ms)	Arati	Dasgupta		artidasgupta@gmail.com
52	LM	L/52/1999	Dr	Siddhartha	Chakraborty	9830030020	sid_ctvs@yahoo.co.in
53	LM	L/53/1999	Dr	Arup Kumar	Ghosh	9230144038	kgarup@hotmail.com
58	LM	L/58/1999	Dr	Amarnath	Ghosh	9903015409	anghosh_4@yahoo.co.in
59	AL	A/59/1999	Mr	Pradip Kumar	das		
60	AL	A/60/1999	Mr	Pranay Kumar	Das	9831622045	pranaykrdas771@gmail.com
61	LM	L/61/1999	Dr	Subrata	Dey	9831223408	subratadey61@yahoo.co.in
62	LM	L/62/2000	Dr	Kishore C	Mukherjee	9830070853	
64	LM	L/64/2000	Dr	Ajay	Kaul	9830025356	kaul@cal3vsnl.net.in
66	LM	L/66/2000	Dr	Amitabha	Chakrabarti	9830022758	amitetal@gmail.com
69	LM	L/69/2001	Dr	Dilip Kumar	Saha	9830056435	
70	AL	A/70/2001	Mr	Debasis	Ray	9831125018	raydeb_per@yahoo.com
71	AL	A/71/2001	Dr	Rajkumar	Ghosh	9831039137	rajkumarghosh@yahoo.com
72	LM	L[72/2001	Dr	Subhasish	Guha	9830321446	drsubhasishguha@gmail.com
73	LM	L/73/2001	Dr	Indrani	Guha	9830032465	tinkee812@yahoo.com
74	LM	L/74/2001	Dr	Prakash Kumar	Sanki	9831061979	prakashsanki@gmail.com
75	LM	L/75/2002	Dr	Jahar Lal	Banerjee	9830251477	

Sl. No.	Type	Memb. No.	Status	First Name	Last Name	Mobile	Email
77	AM	A/77/2002	Dr	Ajoy Kumar	Hazra	9830051856	hazraajoy00064@rediffmail.com
79	AM	A/79/2002	Mr	Loknath	Tiwari	9831497490	aloktp@yahoo.com
80	AM	A/80/2002	Dr	Somnath	Ganguly	9830062013	drsganguli@yahoo.co.in
81	LM	L/81/2002	Dr	Santanu	Dutta	9830808666	santanudutta05@yahoo.com
82	LM	L/82/2002	Dr	Rajarshi	Basu	9830269850	rajarshibasu72@yahoo.com
83	LM	L/83/2002	Dr	Ashim Kumar	Dey	9830792092	drashimdey@yahoo.com
84	LM	L/84/2002	Dr	Kayapanda Muthana	Mandana	9831112359	kmmandana@yahoo.co.uk
87	LM	L/87/2003	Dr	Sushila	Sripad	9433904407	drssripad@gmail.com
88	LM	L/88/2003	Dr	Ratan Kumar	Das	9831987675	ratan_k_das@yahoo.com
90	AM	A/90/2003	Dr	Saibal Roy	Chowdhury	9903571751	doc_saibal@rediffmail.com
93	AM	A/93/2003	Mrs.	Babita	Das	9831949590	pranaykrdas771@gmail.com
94	AM	A/94/2003	Mrs.	Rekha	Banerjee		
96	LM	L/96/2003	Dr	(Ms) Mrinmayi	Ray	9830014773	raymrinmayi@gmail.com
97	LM	L/97/2003	Dr	Atanu	Saha	9830029679	dratanusaha@gmail.com
98	LM	L/98/2003	Dr	Sukanta Kumar	Behera	9831040083	drsukantabehera@gmail.com
99	LM	L/99/2003	Dr	Sadhan Chandra	Ray	9830045577	sadhan.ray@gmail.com
100	AM	A/100/2004	Dr	Tarun Kumr	Saha	9830254416	sahadr.tarun@yahoo.in
101	LM	L/101/2003	Dr	Ashutosh	Raghuvanshi	9830035456	vc_rtiics@rediffmail.com
102	LM	L/102/2004	Dr	Ramesh	Seshadri	9831257836	drrseshadri@gmail.com
103	LM	L/103/2003	Dr	Manoj Kumar	Daga	9748291111	drmanojdaga@gmail.com
104	LM	L/104/2004	Dr	Madhu Sudan	Pal	9434160970	mspalmch@yahoo.co.in
105	AM	A/105/2004	Dr	(Ms) Sudipta	Mukherjee		sid_ctvs@yahoo.co.in
106	AM	A/106/2004	Dr	Narayan Chandra	Garai	9433175321	narayangarai27@gmail.com
107	AM	A/107/2004	Dr	Kali Sankar	Das	9433223554	dr.kali@vsnl.net
108	AM	A/108/2004	Dr	Jyotirmoy	Bandyopadhyay	9831314027	drjyoti0301@gmail.com
109	AM	A/109/2004	Dr	Niranjan	Maiti	9830439743	dr.nmaity@gmail.com

Sl. No.	Type	Memb. No.	Status	First Name	Last Name	Mobile	Email
110	LM	L/110/2004	Dr	Binay Krishna	Sarkar	9433334159	binayskr@hotmail.com
111	LM	L/111/2004	Dr	Javid Veqar	Sadique	9830702701	drjavidvsadique@yahoo.co.in
113	LM	L/113/2005	Dr	Sarajit Kumar	Das	9831450531	sarajitdas@yahoo.com
114	LM	L/114/2005	Dr	Sujay Kumar	Shad	9831888409	
115	LM	L/115/2005	Dr	Mrinalendu	Das	9433095440	dasmrinalendu@hotmail.com
118	AM	A/118/2005	Mr	Radhanath	Samal	9831192992	rnsamal2002@rediffmail.com
119	AM	A/119/2005	Dr	Rabindranath	Chattopadhyay	9433574325	rabindranchatto@gmail.com
123	AM	A/123/2005	Mr	Subodh	Pradhan	9339431402	pradhan.subodh@ymail.com
124	AM	A/124/2005	Mr	Indrajit	Das	9903342006	indrajit003@gmail.com
125	LM	L/125/2005	Dr	Kunal	Hazari	9433146929	drkhazari1@rediffmail.com
126	AM	L/126/2006	Mr	Durgaprassana	Dash	9433146294	durga.dash@nhhospitals.org
127	LM	L/127/2006	Dr	Saptarshi	Roy	9830365395	drsaptarshiroy@yahoo.com
128	AM	A/128/2006	Dr	Manmohan		9331836811	
129	AM	A/129/2006	Mr	Tarun Kumr	Patra		
130	LM	L/130/2006	Dr	Nimish	Rai	9748026608	nimishrai@yahoo.com
131	LM	L/131/2006	Dr	Dhaemendra Kumar	Srivastava	9433831991	
132	LM	L/132/2006	Dr	Anshuman	Mandal	9434331459	anshuman.ctvs@gmail.com
133	AM	A/133/2006	Dr	Dinabandhu	Chatterjee	9830808772	chatterjeed788@gmail.com
134	AM	A/134/2007	Mr	Chittaranjan	Dash	9831979766	chittaranjandash27@yahoo.co.in
135	AM	A/135/2007	Mr	Deblal	Pandit	9831160077	perf_pandit@yahoo.co.in
136	AM	A/136/2007	Mr	Debabrata	Chakraborty	9732087537	deb.perf@gmail.com
137	AM	A/137/2007	Dr	Sudhansu Sekhar	Chatterjee	9830266075	
138	AM	A/138/2007	Mr	Rajib	Das	9830881884	
139	AM	A/139/2007	Mr	Manab	Mitra	9831936139	
140	AM	A/140/2007	Dr	Asis	Mandal	9433074786	dr.asis.mandal.ctvs@gmail.com
141	AM	A/141/2007	Mr	Saurav	Sengupta	9831171219	saurav.srijaa@gmail.com

Sl. No.	Type	Memb. No.	Status	First Name	Last Name	Mobile	Email
142	AM	A/142/2007	Mr	Gautam	Bose		g.bose1963@gmail.com
143	LM	L/143/2007	Dr	Subhendu Sekhar	Mahapatra	9433283336	apurasm@yahoo.co.in
144	AM	A/144/2008	Mr	Kali Sankar	Jana		kalisankarj@yahoo.com
146	AM	A/146/2009	DrMrs.	Chaitali (Dasgupta)	Sen	9330483007	chaitali03@rediffmail.com
147	AM	A/147/2009	Dr	Mrs. kakali	Ghosh	9339748242	gkakali354@gmail.com
148	LM	L/148/2009	Dr	Sanjay	Singh	9836442735	sansingh7@gmail.com
149	LM	L/149/2009	Dr	Kanak Narayan	Bhattacharya	9936131148	kanaknarayan@rediffmail.com
150	LM	L/150/2009	Dr	Sudip	Chowdhury	9007762412	sudipdolly@gmail.com
151	LM	L/151/2009	Dr	Suranjan	Haldar	9836045090	dr.suranjan.haldar@gmail.com
154	AM	A/154/2009	Mr	Tanweer Khursheed	Ahamad	9836325123	tanweerkahrned15@gmail.com
155	AM	A/155/2009	Mr	Tapas	Mondal	9830952003	
157	AM	A/157/2009	Mrs.	Patrisia	Joseph (James)	9831423019	patriciajames29@gmail.com
159	AM	A/159/2009	Mr	Randolf Anto	Vanjour	9230500148	
161	AM	A/161/2009	Dr	Mrs. Reeta	Neogi		
162	LM	L/162/2009	Dr	Debasis	Das	9831852211	dasdeba@yahoo.com
165	AM	A/165/2009	Mr	Soumik	Majumder	9163020767	soumikkolkata@yahoo.com
166	AM	A/166/2009	Mr	Subhasish	Bera	9231978210	subha.perfusion@gmail.com
167	AM	A/167/2009	Mr	Prasanta Kumar	Patra	9007807675	
168	AM	A/168/2009	Mr	Neshat	Alam	9874829984	nazar062@gmail.com
169	AM	A/169/2009	Mr	Subrata	Patra	9831483603	spatra.perf@gmail.com
170	AM	A/170/2010	Mr	Shyamashis	Mitra	9874683054	shyamish-mitra@yahoo.com
171	AM	A/171/2010	Dr	Debasis	Dasadhikari	9239331332	d.dda@rediffmail.com
172	AM	A/172/2010	Dr	Priyadarshan	Konar	9830443132	dr.pkonar@gmail.com
175	AM	A/175/2010	Mrs.	Shila	Chatterjee	9830807364	abikhit1994@gmail.com
176	AM	A/176/2010	Dr	Suchindran	Bandyopadhyay	9830073866	s4cida@yahoo.co.in
177	LM	L/177/2010	Dr	Mrs. Tripti	Talapatra	9038018759	ttalapatra@yahoo.co.in

Sl. No.	Type	Memb. No.	Status	First Name	Last Name	Mobile	Email
178	AM	A/178/2010	Dr	Rajarshi	Ghosh	9830008129	drrajarshighosh@gmail.com
182	LM	L/182/2010	Dr	Zahid Mohammad	Hossain	9804121115	zahidhossain577@gmail.com
183	AM	A/183/2010	Mr	Tanmay	Acharia	9831671725	tanmay_05@yahoo.com
184	AM	A/184/2010	Mrs	Minakshi	Mondal	9748178566	
185	LM	L/185/2010	Dr	Sumanta	Das	9836230551	drsumantadas@yahoo.co.in
186	AM	A/186/2010	Mr	Kamal	Das	8013485762	kamaldas86@gmail.com
187	AM	A/187/2010	Mr	Sanjay	Das	9830177458	sanpiku_joy@yahoo.com
188	LM	L/188/2010	Dr	Bhaskar	Das	9231674673	doctorbhaskardas@rediffmail.com
189	AM	A/189/2010	Dr	Mrs. Sanjukta	Ray	9433054563	dr.sanjuktaray@hotmail.com
190	AM	A/190/2010	Dr	Subhendu	Sarkar	9831171162	sarkar_suhendu@yahoo.com
							subhendusarkar757@gmail.com
192	AM	A/192/2010	Mrs.	Bipasha	Datta	9830522705	
193	LM	L/193/2011	Dr	Dipayan	Ghosh	9433041995	dipayanghosh291@yahoo.co.in
194	AM	A/194/2011	Mr	Raghunandan	Raghavan	8293450097	
195	AM	L/195/2011	Dr	Kaushik	Mukherjee	8420966115	drmukherjeekaushk@yahoo.com
196	AM	A/196/2011	Dr	Sandip	Sardar	9831054978	dip.ctvs@gmail.com
197	LM	L/197/2011	Dr	Arunansu	Dhole	9477058388	dhole.arunansu@rediffmail.com
198	LM	L/198/2011	Dr	Kuntal	Roy Chowdhuri	9932868298	kuntalroychowdhuri@mail.com
201	LM	L/201/2011	Dr	Rupesh	Kumar	9883690388	rkctvs@gmail.com
202	AM	A/202/2011	Dr	Poornima	Sivakumar	9163889213	poornima.sivakumar@gmail.com
203	AM	A/203/2011	Dr	Biswajeet	Mohapatra	8017368144	drbiswa135@gmail.com
204	AM	A/204/2011	Mr	Edison Vijayaraj	Charles	9831390035	edison_charles@yahoo.co.in
205	AM	A/205/2011	Mrs.	Arpita	Nag	9874694063	nag_arpita@rediffmail.com
206	AM	A/206/2011	Dr	Ashutosh	Samal	9438326402	samalashutosh16@gmail.com
207	LM	L/207/2011	Dr	Sudhir	B. V.	8023435465	
208	AM	A/208/2011	Dr	Biswajt	Bandyopadhyay	9831115304	bisban@rediffmail.com

Sl. No.	Type	Memb. No.	Status	First Name	Last Name	Mobile	Email
209	AM	A/209/2011	Ms.	Baby	Das	9836646694	
210	LM	L/210/2011	Dr	Manujesh	Bandyopadhyay	9874430370	manujeshbandyopadhyay@gmail.com
211	AM	A/211/2011	Dr	Asif	Iqbal	9836850632	aifanesthesia@gmail.com
212	AM	A/212/2012	Dr	Jayita	Chakrabarti	9477174869	jayitachakrabarti@yahoo.com
213	LM	L/213/2012	Dr	Pradeep	Narayan	8017249115	pradeepdoc@gmail.com
214	LM	L/214/2012	Dr	Ashis	Haldaer	9051141356	drashishalder@gmail.com
215	LM	L/215/2012	Dr	Amanul	Hoque	9477074046	dr.amanul.hoque@gmail.com
216	AM	L/216/2012	Dr	Debabrata	Biswas	9239036876	drdeba07@rediffmail.com
217	LM	L/217/2012	Dr	Sudipto	Bhattacharya	9007212232	dr.sudiptob@gmail.com
218	AM	L/218/2012	Dr	Md. Rashid	Zeya Ayubi	7890259539	rash_kmc03@yahoo.com
219	AM	L/219/2012	Dr	Soumyajit	Ghosh	9830374458	drsghosh1982@gmail.com
220	AM	A/220/2012	Dr	Amar Nath	Shaw	9432894392	dr_amarnath2002@yahoo.co.in
221	AM	L/221/2012	Dr	Abhijit	Sengupta	9831332625	vsg1167@gmail.com
222	AM	A/222/2012	Dr	RS Arun	Visvarajan	8442980911	arunvisvarajan@gmail.com
223	LM	L/223/2012	Dr	Prasanta	Das	8013215248	prasantadas700061@yahoo.com
224	AM	A/224/2012	Dr	Surendra Singh	Yadav	8192101106	drsurendrayadav21@gmail.com
225	LM	L/225/2012	Dr	Swarnendu	Datta	9477837608	swarnendudatta@yahoo.co.in
226	LM	L/226/2013	Dr	Ushnish	Chakrabarti	9433801924	dr.u.chakrabarty@gmail.com
227	AM	L/227/2012	Dr	Subhash	Minda	9903999453	mindasubhash@gmail.com
228	LM	L/228/2013	Dr	Nilanjan	Dutta	9836720202	dr.duttanilanjan@rediffmail.com
229	LM	L/229/2013	Dr	Dipankar	Ganguly	9804000400	drdipankar_g@apollohospitals.com, dipu_joy@hotmail.com
230	LM	L/230/2013	Dr	Amit	Banerjee	8582894477	dramitbanerjee@gmail.com
231	AM	A/231/2013	Dr	Anton Prem	Thilak	9843910265	premthilak87@gmail.com
232	AM	A/232/2013	Dr	Devika	Thacker	8895391210	devikathacker@gmail.com
233	AM	A/233/2013	Dr	Gautam	Shetty	9556704627	drgauthamshetty@gmail.com

Sl. No.	Type	Memb. No.	Status	First Name	Last Name	Mobile	Email
234	AM	A/234/2013	Dr	Santosh Kumar	Pandey	9163680789	drpandey2005@yahoo.com
235	AM	A/235/2013	Dr	Manoj	Bhargava	9617078999	pscmulthan@gmail.com
236	LM	L/236/2013	Dr	Pradip Kumar	Sarkar	9051419540	sarkarp2000@yahoo.co.uk
237	LM	A/237/2013	Dr	Dhiraj	Barnan	9674578441	drdhirajbarman@gmail.com
238	AM	A/238/2013	Dr	Krishnendu	Chakrabarti	9432228326	krishnendu_chakrabarti@rediffmail.com
239	LM	L/239/2013	Dr	Devraj	Kumar	8420063897	medico.dev@gmail.com
240	AM	A/240/2014	Mr	Sukanta	Maity	9433456389	sukantamaity002@gmail.com
241	AM	A/241/2014	Mr	Debasis	Das	9831807794	dedoplus@gmail.com
242	AM	A/242/2014	Mr	Arkaprabho	Das	8961201909	arkaprabho@gmail.com
243	AM	A/243/2014	Dr	Shilpa	Basu Roy	9831480813	drshilpa@aol.com
244	AM	A/244/2014	Dr	Debi Prasanna	Ghosal	9830185509	debiprasannaghosal@gmail.com
245	LM	L/245/2014	Dr	Mohammed Wasim	Khan	8017251181	drwazimkhan@gmail.com
246	AM	A/246/2014	Mr	Ritesh Kumkar	Choudhary	8013242845	riteshchoudhary.pas@gmail.com
247	AM	A/247/2014	Mr	Rakesh Kumar	Pandit	9681178588	antioxidant007@gmail.com
248	AM	A/248/2014	Mr	Jit	Adhikary	9830440356	jit.adhikary@nhhospitals.org
249	AM	A/249/2014	Mr	Shyamal Kumar	Maiti	9830729483	shyamalmaiti.pa@gmail.com
250	AM	A/250/2014	Mr	Tanmoy Kumar	Kandar	9836015855	tanmoy.india.pa@gmail.com
251	AM	A/251/2014	Mr	Subhadeep	Datta	9748620466	dattasubhadeep13@gmail.com
252	AM	A/252/2014	Mr	Sandip	Paul	9883219224	sandippaul61@gmail.com
253	LM	L/253/2014	Dr	Arijit	Datta	9830427104	drarijitdatta@gmail.com
254	AM	A/254/2014	Dr	Dipanjan	Chatterjee	9903476445	drdipanjan@gmail.com
255	LM	L/255/2014	Dr	Soumik	Pal	9477522682	drsoumikpal@gmail.com
256	AM	A/256/2014	Mr	Sushovan	Das	9143396284	das_sushovan@ymail.com
257	AM	A/257/2014	Dr	Shruti	Banerjee	9674346173	drshrutibanerjee@gmail.com
258	LM	A/258/2014	Dr	Biswarup	Purkayastha	9854029812	biswarup2001@gmail.com
261	AM	A/261/2014	Ms.	Sheli	Phani	9647639308	sheliphani@gmail.com

Sl. No.	Type	Memb. No.	Status	First Name	Last Name	Mobile	Email
263	AM	A/263/2014	Dr	Sayar Kumar	Munshi	9836249399	drsayar.munshi@gmail.com
264	AM	A/264/2014	Dr	Arnab	Maity	9748544330	mailadoctor@gmail.com
265	AM	A/265/2014	Dr	Debajyoti	Mandal	9433892340	debajyoti.mandal@gmail.com
266	AM	A/266/2014	Dr	Harish K	Sinha	8274945078	harishsinhakmc@gmail.com
267	AM	A/267/2014	Mr	Biswajit	Jana	9732492749	biswajit.jana69@gmail.com
268	AM	A/268/2014	Mr	Sumanta	Ghosh	8670858525	sumantoghosh491@gmail.com
269	LM	L/269/2014	Dr	Saibal	Gupta	9831015774	drsaibalgupta@hotmail.com
270	LM	L/270/2014	Dr	Siddharth	Pahwa	9007508980	siddharthpahwa@gmail.com
271	AM	A/271/2014	Dr	Bhubandeep	Mukhopadhyay	9432015168	bhubandeep@gmail.com
272	LM	L/272/2015	Dr	Tinni	Mitra	9831010012	drtinnimitra@rediffmail.com
273	AM	A/273/2015	Dr	Sanjit Kumar	Mondal	9007703800	mondaldrsanjitkumar@yahoo.in
274	LM	L/274/2015	Dr	Suraj Kumar	Pradhan	9002499261	surajprdhan@yahoo.co.in
275	AM	A/275/2015	Dr	Ravi	Ambastha	8981948597	ambastha7@gmail.com
276	AM	A/276/2015	Dr	Raja	Lahiri	9935615903	rajalahiri.imsbhu@gmail.com
277	LM	A/277/2015	Dr	Shravan	Kumar	9749150999	shravank10@gmail.com
278	AM	A/278/2015	Dr	Subhajit	Sharma	9749225034	subhajitsharma.maynaguri@gmail.com
279	AM	A/279/2015	Ms.	Sweta	Neogi	9432519207	swetaneogi@yahoo.com
280	AM	A/280/2015	Ms.	Jui	Upadhaya	8017138741	shortcuttojui@gmail.com
281	AM	A/281/2015	Dr	Shilpa	Gandhi	8800359233	msshilpagandhi@gmail.com
282	AM	A/282/2015	Mr	Ajit Kumar	Singh	9239436010	ajit.kumar939@gmail.com
283	AM	A/283/2015	Dr	S. Uma Maheswara	Rao	8335879400	umasukamanchi@gmail.com
284	AM	A/284/2015	Dr	Shreyas Prakash	Potdar	8017036677	shailprakash2512@gmail.com
285	AM	A/285/2015	Dr	Arif G Khaja	Shaik	9163063121	drshaikarif@yahoo.in
286	AM	A/286/2016	Dr	Pranshu	Pandey	9163043423	pranshurules@gmail.com
287	LM	L/287/2016	Dr	Swarup Kumar	Pal	9699559007	puraws@gmail.com
288	LM	L/288/2016	Dr	Siddharth	Sarangi	8335046707	sarangi.siddharth@gmail.com

Sl. No.	Type	Memb. No.	Status	First Name	Last Name	Mobile	Email
289	LM	L/289/2016	Dr	Sankhadip	Pramanik	7890601747	drsankhadippramanik@gmail.com
290	AM	A/290/2016	Dr	Gaurav	Patni	9073393592	drgauravpatni17@gmail.com
291	AM	A/291/2016	Dr	Neeraj Kumar	Jha	9641617075	neerajjhanbmch@gmail.com
292	AM	A/292/2016	Dr	Pratik	Pandey	9907958065	pratikpandey05@gmail.com
293	AM	A/293/2016	Dr	Madhur	Sahay	9771492176	madhursahay@gmail.com
294	AM	A/294/2016	Dr	Sushil Kumar	Nayak	9874595549	sushilnayak@gmail.com
295	AM	A/295/2016	Dr	Swetabh	Suman	9472211951	thakurswetabh@gmail.com
296	AM	A/296/2016	Dr	Saikat	Chaudhuri	7507828300	saikical13@gmail.com
297	AM	A/297/2016	Ms.	Tanuja	Charit	9903614648	tanujacharit@gmail.com
298	AM	A/298/2016	Dr	Chaina	Paul	8926578975	chainapaul.dwip@gmail.com
299	AM	A/299/2017	Dr.	Saumik	Saha	9748302295	saumiksaha001@gmail.com
300	AM	A/300/2017	Ms.	Tapati	Roy	9477373895	tamalikar16@gmail.com
301	AM	A/301/2017	Dr	Patralekha	Das	9831376706	grungegirl18@gmail.com
302	AM	A/302/2017	Dr	Yashaskar	M	9008456431	doc.yashaskar@gmail.com
303	AM	A/303/2017	Dr	Arya Kamal	Das	9435070890	draryakamaldas@gmail.com
304	AM	A/304/2017	Dr	Samarth	Acharya	9883975021	dr.samarthacharya23@gmail.com
305	AM	A/305/2017	Dr	Gourhari	Das	9464034890	gaurharidas89@gmail.com
306	AM	A/306/2018	Dr.	Asher Georje	Joseph	8709263837	asherlara4@gmail.com
307	AM	A/307/2018	Dr.	Nilaksha	Bhattacharjee	9706131469	bhattacharjeenilaksha@gmail.com
308	AM	A/308/2018	Dr.	Ajil	Joseph	9742834263	ajilj41@gmail.com
309	AM	A/309/2018	Dr.	Rohit Kumar	Rathi	9717799461	dr.rohitrathi@gmail.com
310	AM	A/310/2018	Dr.	Manas Kumar	Sahoo	8481940935	manasksahoo@gmail.com
311	AM	A/311/2018	Dr.	Minhajuddin	Khurram	9980395548	dr.khurram.minhaj@gmail.com
314	AM	A/314/2018	Dr	Ahmed Salim Azhar	Sayyed	8668544368	mesayyedazhar@gmail.com
315	AM	A/315/2018	Mr	Dipayan	Chakraborty	9609173787	dipayanchakraborty16pft@gmail.com
316	AM	A/316/2018	Dr	Ahmed Salim Azhar	Sayyed	8668544368	mesayyedazhar@gmail.com

Sl. No.	Type	Memb. No.	Status	First Name	Last Name	Mobile	Email
317	LM	L/317/2018	Dr	Ashima	Bhelotkar	9748044285	drashimacvts@gmail.com
318	LM	L/318/2018	Dr	Avishek	Samaddar	8727088067	see_avishek@yahoo.co.in
319	AM	A/319/2019	Ms.	Sabnam	Mohanty	9830236582	sabnam.leo94@gmail.com
320	LM	L/320/2019	Dr	Shubhadev	Bhattacharya	9830385788	deep.dhuvo@gmail.com
321	AM	A/321/2019	Dr	Soumya Dar	Sanyal	9051393846	soumyadarshon@gmail.com
322	AM	A/322/2019	Dr	Rahul	Bose	9611580939	r8756@gmail.com
323	AM	A/323/2019	Dr	Diptimoy			
324	AM	A/324/2019	Dr	Sufina	Shales	9952968478	sufinashalespk@gmail.com
325	AM	A/326/2019	Dr	Hari Govind	Varma	7204926902	harigovindvarma@gmail.com
326	AM	A/327/2019	Dr	Subhendu	Adhikari	9434113709	subhendubsmc90@gmail.com
327	AM	A/328/2019	Dr	Unmesh	Chakraborty	9007123656	halo.zico@gmail.com
328	AM	A/329/2019	Dr	Areeb Ahmad	Khan	9035297163	aakregilu@gmail.com
329	AM	A/330/2019	Dr	Amitrajit	Dasgupta	9433047540	docdasgupta@gmail.com
330	AM	A/331/2021	Dr	Sukhendu	Maity	8101239926	maitysukhendu1993@gmail.com
331	AM	A/332/2021	Dr	Debmalya	Saha	8444802200	debmalya.cmc@gmail.com
332	AM	A/333/2022	Dr	Surajit	Sarkar	9547099649	surajitsarkar18@gmail.com
						7003971781	
333	AM	A/334/2022	Dr	Nabarun	Mallick	9874958365	me.nabarun@gmail.com
334	AM	A/335/2022	Dr	Debtanu	Hazra	8620033601	drdebtanuhazra2016@gmail.com
335	AM	A/336/2022	Dr	Akash		8348775007	akri2015om@gmail.com
336	AM	A/337/2022	Dr	Rituparna	Dasgupta	8987407905	rdgalways@gmail.com
337	AM	A/338/2022	Dr	Debashis Kumar	Sain	8250350672	aryakumarsain@gmail.com
338	AM	A/339/2022	Dr	Ritik	Hooda	9811188056	dr.ritik.hooda@gmail.com
339	AM	A/340/2022	Dr	Shubham	Gupta	7872994823	shubhamguptaynr021@gmail.com
340	AM	A/341/2022	Dr	Bharath	S	8072928639	bharathsaske@gmail.com
341	AM	A/342/2022	Dr	Susovan	Halder	8012847668	

Sl. No.	Type	Memb. No.	Status	First Name	Last Name	Mobile	Email
342	AM	A/343/2022	Dr	Apu	Saha	8240361587	apunrs2014@gmail.com
343	AM	A/344/2022	Dr	Binayak	Chanda	9007025555	
344	AM	A/345/2023	Dr	Mazahurul	Islam	8638619218	mazahurulislam120@gmail.com
345	AM	A/346/2023	Dr	Payel	Sarkar	8910345064	payelsarkar957@gmail.com
346	AM	A/347/2023	Dr	Riddhika	Majumder	8599099799	riddhikamajumder@gmail.com
347	AM	A/348/2023	Dr	Ronmita	Pal	9836912350	ronmitapal@gmail.com
348	AM	A/349/2023	Dr	Soumya	Guha	9999790836	dr.soumya.guha@gmail.com
349	AM	A/350/2023	Dr	Nilotpal	Behuria	7030478678	nilsmash5622@yahoo.co.in
350	AM	A/351/2023	Dr	Ravi Tej	Golive	8159086780	tej.golive@gmail.com
351	AM	A/352/2023	Dr	Sourav	Paik	9903254159	dr.s.paik@gmail.com
352	AM	A/353/2023	Dr	Aparna	Basumatary	8638356008	aparnabasumatary@gmail.com
353	AM	A/354/2023	Dr	Richa	Srivastawa	7003661644	richasrivastwa14@gmail.com
354	AM	A/355/2023	Dr	Vishwa Prakash	Das	9433253176	dr.vishwaprakash@gmail.com
355	AM	A/356/2023	Dr	Abhinaba	Sarkar	8918665872	abhinrs.md@gamil.com
356	AM	A/357/2023	Dr	Anit	Kumar	9122924363	dr.anit2k13@gmail.com
357	AM	A/358/2023	Dr	Rajesh	Kumar V.	8072650167	rajeshkumarv1998@gmail.com
358	AM	A/359/2023	Dr	Kunal	Patel	9902927902	kunalpatel173@gmail.com
359	AM	A/360/2023	Dr	Pritish Kumar	Nayak	7978029554	pritishnkol@gmail.com
360	AM	A/361/2023	Dr	Shivangi	Jain	7980554812	shivangi1965@gmail.com
361	LM	L/361/2023	Dr	Arumit	Palit	9821538681	arumitpalit@gmail.com
362	AM	A/362/2023	Ms	Ashmira	Hossain	9836048955	ashmira.manabi@gmail.com
363	AM	A/363/2023	Mr	Saibal	Tripathy	9933955903	saibaltripathy.perfusionist@gmail.com
364	AM	A/3642023	Dr	Arnab	Pal	6290235388	arnabtukaripaul@gmail.com
365	AM	A/365/2023	Mr	Pranabesh	Paria	8017125620	pranabeshparia150@gmail.com
366	AM	A/366/2023	Dr	Tanulina	Sarkar	9875483646	tkltsarkar@gmail.com
367	LM	L/367/2023	Dr	Shandan	Kumar	9986247424	chandananat@gmail.com
368	LM	L/368/2023	Dr	Niket	Arora	8939455073	drniketarora@gmail.com

Association of
Thoracic and Cardio Vascular Surgeons
of West Bengal

Acknowledges the help and co-operation received from all concerned to bring out this Cardio Thoracic News, Volume 7, No. 3, November 2023 issue.

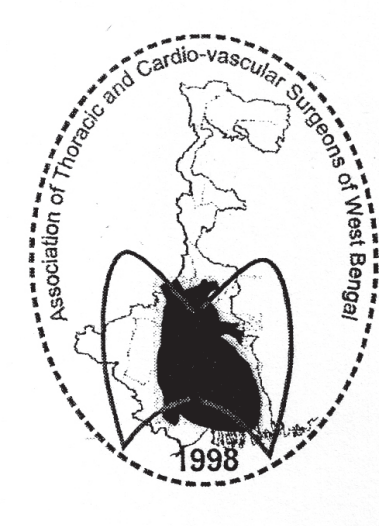

Thank you all.


Association of Thoracic and Cardio Vascular Surgeons of West Bengal
1998
Silver Jubilee
Annual Scientific Meet 2023
ATCVSWB & NEEACTS
4th-5th November, 2023
Venue: Hotel Fairfield By Marriott, Kolkata
Moodran Graphica